

horses, cattle, pigs, rats, squirrels, bats, and chickens, have been reported to be seropositive for CHIKV (2,6–8).

These results indicate that CHIKV infects long-tailed macaques in Malaysia, but seroprevalence rates are low, and there is little evidence of viremia, except at the 1 specific site in Kuala Lipis. Although experimental infection of long-tailed macaques resulted in detectable CHIKV antigen in macrophages for  $\geq 3$  months, infectious CHIKV is not detectable beyond 44 days (10), and long-term neutralizing immunity is present for  $\geq 180$  days (5). However, there is no evidence for long-term active CHIKV infection and its recrudescence in macaques or humans.

A limitation of our study was the relatively small number of monkeys sampled. Although we found no overall significant correlation between incidence of human cases of infection with CHIKV and estimated number of long-tailed macaques per 100,000 persons in each state ( $r^2 = 0.05$ ,  $p = 0.49$ ), we cannot exclude the involvement of long-tailed macaques in a local outbreak at a specific site. Long-term dynamics of antibodies against CHIKV in long-tailed macaques are not known, which might affect sensitivity of detection assays.

We conclude that long-tailed macaques in conflict with humans in specific areas probably played a small part in transmission of CHIKV during recent large outbreaks in humans in Malaysia. Human–mosquito–human transmission and travel by infected humans were probably the major factors involved in spread of this virus. If a true sylvatic reservoir that effectively maintains CHIKV is present in Malaysia, long-tailed macaques might play only a minor role. In addition, involvement of other NHPs and mammals remains to be elucidated.

This study was supported by the University of Malaya (High Impact Grant E000013-20001 and grant RG526-13HTM).

## References

1. Rougeron V, Sam IC, Caron M, Nkoghe D, Leroy E, Roques P. Chikungunya, a paradigm of neglected tropical disease that emerged to be a new health global risk. *J Clin Virol*. 2015; 64:144–52. <http://dx.doi.org/10.1016/j.jcv.2014.08.032>
2. Diallo M, Thonnon J, Traore-Lamizana M, Fontenille D. Vectors of chikungunya virus in Senegal: current data and transmission cycles. *Am J Trop Med Hyg*. 1999;60:281–6.
3. Karuppannan K, Saaban S, Mustapa AR, Zainal Abidin FA, Azimat NA, Keliang CJ. Population status of long-tailed macaque (*Macaca fascicularis*) in Peninsular Malaysia. *Journal of Primatology*. 2014;3:2.
4. Chua KB. Epidemiology of chikungunya in Malaysia: 2006–2009. *Med J Malaysia*. 2010;65:277–82.
5. Kam YW, Lee WW, Simarmata D, Le Grand R, Tolou H, Merits A, et al. Unique epitopes recognized by antibodies induced in chikungunya virus-infected non-human primates: implications for the study of immunopathology and vaccine development. *PLoS ONE*. 2014;9:e95647. <http://dx.doi.org/10.1371/journal.pone.0095647>
6. Halstead SB, Udomsakdi S. Vertebrate hosts of chikungunya virus. *Bull World Health Organ*. 1966;35:89.
7. Marchette NJ, Rudnick A, Garcia R, MacVean DW. Alphaviruses in Peninsular Malaysia: I. Virus isolations and animal serology. *Southeast Asian J Trop Med Public Health*. 1978;9:317–29.
8. Vourc'h G, Halos L, Desvars A, Boué F, Pascal M, Lecollinet S, et al. Chikungunya antibodies detected in non-human primates and rats in three Indian Ocean islands after the 2006 ChikV outbreak. *Vet Res*. 2014;45:52. <http://dx.doi.org/10.1186/1297-9716-45-52>
9. Apandi Y, Nazni WA, Noor Azleen AZ, Vythilingam I, Noorazian MY, Azahari AH, et al. The first isolation of chikungunya virus from nonhuman primates in Malaysia. *Journal of General and Molecular Virology*. 2009;1:35–9.
10. Labadie K, Larcher T, Joubert C, Mannioui A, Delache B, Brochard P, et al. Chikungunya disease in nonhuman primates involves long-term viral persistence in macrophages. *J Clin Invest*. 2010;120:894–906. <http://dx.doi.org/10.1172/JCI40104>

Address for correspondence: I-Ching Sam, Department of Medical Microbiology, Faculty of Medicine, University of Malaya, Kuala Lumpur 50603, Malaysia; email: jicsam@ummc.edu.my

## Functional Immune Reconstitution by Interleukin-2 Adjunctive Therapy for HIV/ Mycobacterial Co-infection

Jan Heyckendorf, Sven Philip Aries, Ulf Greinert, Elvira Richter, Holger Schultz, Christoph Lange

Author affiliations: Research Center, Borstel, Germany (J. Heyckendorf, U. Greinert, E. Richter, H. Schultz, C. Lange); German Center for Infection Research, Borstel (J. Heyckendorf, U. Greinert, C. Lange); Elbpneumologie, Hamburg, Germany (S.P. Aries); Karolinska Institute, Stockholm, Sweden (C. Lange); University of Namibia School of Medicine, Windhoek, Namibia (C. Lange)

DOI: <http://dx.doi.org/10.3201/eid2109.150461>

**To the Editor:** We describe a case of an immunocompromised patient with AIDS who sought treatment for immunotolerance to an invasive, systemic mycobacterial infection that was unresponsive to antimycobacterial therapy alone. The 41-year old man sought treatment in November 2006 for fatigue, dyspnea, and epigastric pain of 4 weeks' duration and weight loss of 10 kg. HIV-1 infection (20 cells/mL CD4+ T-cells, viral load 230,000 genome equivalents/mL) was diagnosed. Antiretroviral therapy (ART) and *Pneumocystis pneumonia* prophylaxis were initiated.

In June 2007, acid-fast bacilli (AFB) were detected on mediastinal lymph node specimens obtained by endobronchial-ultrasound-guided biopsy during a bronchoscopy; empiric antituberculosis treatment was initiated. *Mycobacterium tuberculosis* DNA was not detected by nucleic acid amplification on these specimens. At the time of referral to our clinic, the physical examination revealed

generalized lymphadenopathy and oral leukoplakia. The patient's bodyweight was 63 kg. Computed tomography showed extensive mediastinal and abdominal lymphadenopathy without other abnormalities. Serologic investigations showed negative results for hepatitis A, B, C, and syphilis. Esophageal-gastro duodenoscopy showed a cottage cheese-like appearance of the duodenal mucosa, and histopathological examination of biopsies documented massive numbers of AFB (online Technical Appendix Figure, panel A, <http://wwwnc.cdc.gov/EID/article/21/9/15-0461-Techapp1.pdf>). Nucleic acid amplification of 16S rRNA from biopsies was performed, and sequence comparison to the National Center for Biotechnology Information database identified the presence of *M. tilburgii*. In July 2007, specific treatment against infection with *M. tilburgii* was initiated with rifabutin, ethambutol, and azithromycin (1).

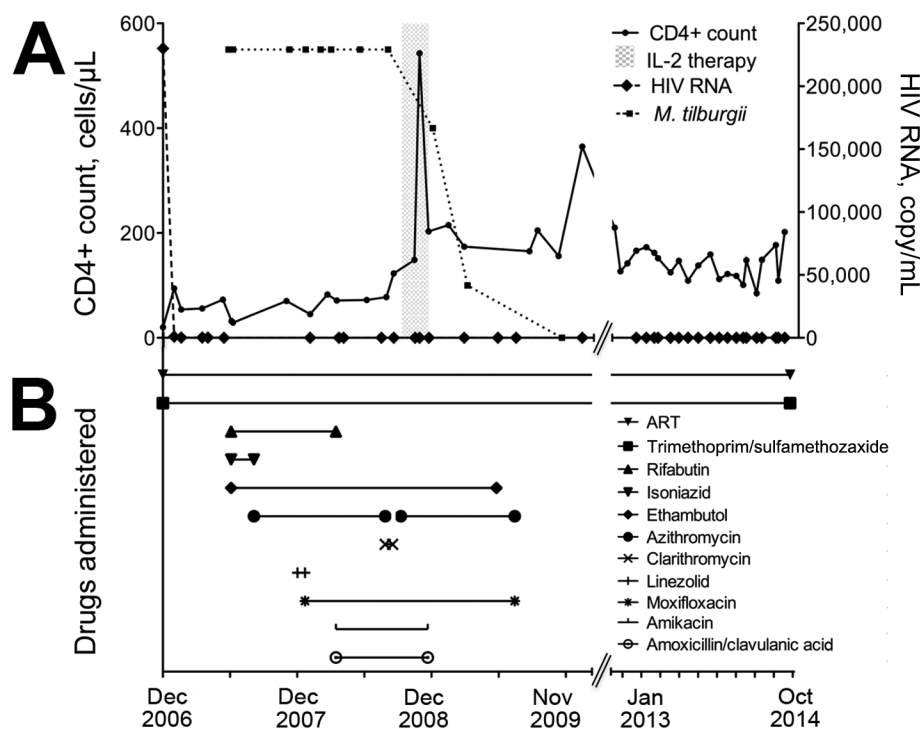
Despite nondetectable levels of viral replication while the patient was receiving ART, CD4+ T cell count did not rise above 73 cells/mL (Figure). In November 2007, he reported diarrhea and weight loss of 6 kg (total weight 57 kg); testing showed hypochromic-microcytic anemia (hemoglobin 8.2 g/dL). Bone marrow biopsy showed infiltration of AFB, and 16S rRNA amplification confirmed *M. tilburgii* infection. Macroscopic and microscopic appearance of the duodenal mucosa was unchanged.

During the next 10 months, antimycobacterial therapy had to be altered as a consequence of adverse drug events (Figure). In November 2007, treatment with linezolid resulted in an allergic reaction with generalized rash and

fever. In March 2008, treatment with rifabutin was discontinued after pancytopenia developed. Treatment with amikacin between March and November 2008 resulted in hearing loss. During this time, the patient's symptoms improved, and he gained 16 kg (total weight: 73 kg) when he received pulsed doses of prednisolone (20 mg/dL), but he had diarrhea when steroids were tapered to 10 mg/dL. By August 2008, after >1 year of antimycobacterial therapy, there were no improvements of clinical findings.

Adjunctive treatment with interleukin-2 (IL-2 [Proleukin S, Novartis Pharma GmbH, Nuremberg, Germany]) was administered subcutaneously ( $4.5 \times 10^6$  IU) on 3 occasions in September, October, and November 2008. The mean post-IL-2 treatment CD4+ cell count was 242/mL, an improvement over 64/mL before the intervention (Figure). In November 2009, the duodenal mucosa appeared normal on inspection, and no bacteria were found on histopathological examinations (online Technical Appendix Figure, panel B). Antimycobacterial therapy (Figure) was discontinued, steroid administration was gradually reduced, and measured bodyweight stabilized (72–74 kg). At the last examination in December 2014, the patient remained free of signs and symptoms of recurrence of *M. tilburgii* infection.

*M. tilburgii* is an uncultivable nontuberculous mycobacterium related to *M. simiae* and *M. genavense* (2). Fewer than 10 clinically relevant cases of *M. tilburgii* infections have been described in the literature (2–7); most were intestinal infections in immunocompromised hosts (3). Successful treatment has been achieved with combination



**Figure.** Laboratory findings and drug treatment regimen over time for an HIV-infected patient with disseminated *Mycobacterium tilburgii* infection, December 2006–October 2014. A) CD4+ T cell count, HIV viral load, and use of interleukin-2 (IL-2; gray shading). B) Antimycobacterial drug combinations, antiretroviral therapy (ART), and trimethoprim/sulfamethoxazole prophylaxis.

regimens of antimycobacterial drugs that are also effective against *M. avium* complex (4).

In 2 studies that evaluated the effect of adjunctive IL-2 therapy in addition to ART for previously treatment-naïve patients with HIV infection, baseline median numbers of circulating CD4+ cells increased significantly, but expansion of CD4+ T cells was not associated with the reduction in the risk for opportunistic diseases or death (8). In contrast to these results, in a study of HIV-positive patients who had low circulating CD4+ T cell counts, the participants experienced fewer AIDS-defining events and fewer deaths occurred when they were treated with adjunctive IL-2 immunotherapy (9).

This case report provides lessons for the understanding of mycobacterial diseases. First, despite massive infiltration of duodenal mucosa, mesenteric lymph nodes, and bone marrow, the lack of inflammatory responses in this patient prevented tissue destruction. Second, in the absence of a sufficient immune response and an increase in the number of circulating CD4+ T cells, antimycobacterial therapy without adjunctive immunotherapy did not clear the systemic bacterial infection.

Host responses to pathogens are not always beneficial. Intense immune reactions experienced during episodes of sepsis or HIV immune reconstitution inflammatory syndrome are frequently associated with patient death. Alternately, in the absence of inflammatory responses to pathogens, the patient is unprotected, and even microbiota that are harmless to an immunocompetent person can adversely invade. In an optimal immune response setting, a balance between proinflammatory and anti-inflammatory factors in response to pathogens is maintained (10).

C.L. is funded by the German Center for Infection Research (DZIF).

## References

- Griffith DE, Aksamit T, Brown-Elliott BA, Catanzaro A, Daley C, Gordin F, et al. An official ATS/IDSA statement: diagnosis, treatment, and prevention of nontuberculous mycobacterial diseases. *Am J Respir Crit Care Med*. 2007;175:367–416. <http://dx.doi.org/10.1164/rccm.200604-571ST>
- Hartwig NG, Warris A, van de Vosse E, van der Zanden AG, Schülin-Casonato T, van Ingren J, et al. “*Mycobacterium tuberculosis*” infection in two immunocompromised children: importance of molecular tools in culture-negative mycobacterial disease diagnosis. *J Clin Microbiol*. 2011;49:4409–11. <http://dx.doi.org/10.1128/JCM.05460-11>
- Wagner D, Vos MC, Buiting AGM. “*Mycobacterium tuberculosis*” infections. *Emerg Infect Dis*. 2006;12:532–4. <http://dx.doi.org/10.3201/eid1203.051139>
- Temmerman S, Vandekerckhove L, Sermijn E, Vogelaers D, Claeys G, Vaneerchoutte M, et al. Disseminated infection with *Mycobacterium tuberculosis* in a male immunocompromised patient. *J Clin Microbiol*. 2014;52:1777–9. <http://dx.doi.org/10.1128/JCM.03148-13>
- Palmore TN, Shea YR, Conville PS, Witebsky FG, Anderson VL, Rupp Hodge IP, et al. “*Mycobacterium tuberculosis*,” a newly described, uncultivated opportunistic pathogen. *J Clin Microbiol*. 2009;47:1585–7. <http://dx.doi.org/10.1128/JCM.02385-08>
- Schepers K, Schandené L, Bustamante J, Van Vooren J-P, de Suremain M, Casanova J-L, et al. IL-12Rβ1 deficiency and disseminated *Mycobacterium tuberculosis* disease. *J Clin Immunol*. 2013;33:1285–8.
- Kolditz M, Halank M, Spornraft-Ragaller P, Schmidt H, Höffken G. Localized pulmonary infection associated with *Mycobacterium tuberculosis* in an HIV-infected patient. *Infection*. 2005;33(4):278–81.
- INSIGHT-ESPRIT Study Group, SILCAAT Scientific Committee; Abrams D, Levy Y, Losso MH, Babiker A, Collins G, Cooper DA, et al. Interleukin-2 therapy in patients with HIV infection. *N Engl J Med*. 2009;361:1548–59. <http://dx.doi.org/10.1056/NEJMoa0903175>
- Fontas E, Kousignian I, Pradier C, Poizot-Martin I, Durier C, Weiss L, et al. IL-2 therapy: potential impact of the CD4 cell count at initiation on clinical efficacy—results from the ANRS CO4 cohort. *J Antimicrob Chemother*. 2010;65:2215–23. <http://dx.doi.org/10.1093/jac/dkq296>
- Kaufmann SH, Lange C, Rao M, Balaji KN, Lotze M, Schito M, et al. Progress in tuberculosis vaccine development and host-directed therapies—a state of the art review. *Lancet Respir Med*. 2014;2:301–20. [http://dx.doi.org/10.1016/S2213-2600\(14\)70033-5](http://dx.doi.org/10.1016/S2213-2600(14)70033-5)

Address for correspondence: Christoph Lange, Division of Clinical Infectious Diseases, German Center for Infection Research, Clinical Tuberculosis Unit, Research Center Borstel, Parkallee 35, 23845 Borstel, Germany; email: clange@fz-borstel.de

## ***Corynebacterium bovis* Eye Infections, Washington, USA, 2013**

**Siu-Kei Chow, Uyen Bui, Jill E. Clarridge**

Author affiliations: University of Washington, Seattle, Washington, USA (S.-K. Chow, J.E. Clarridge); Veterans Administration Puget Sound Health Care System, Seattle (U. Bui, J.E. Clarridge)

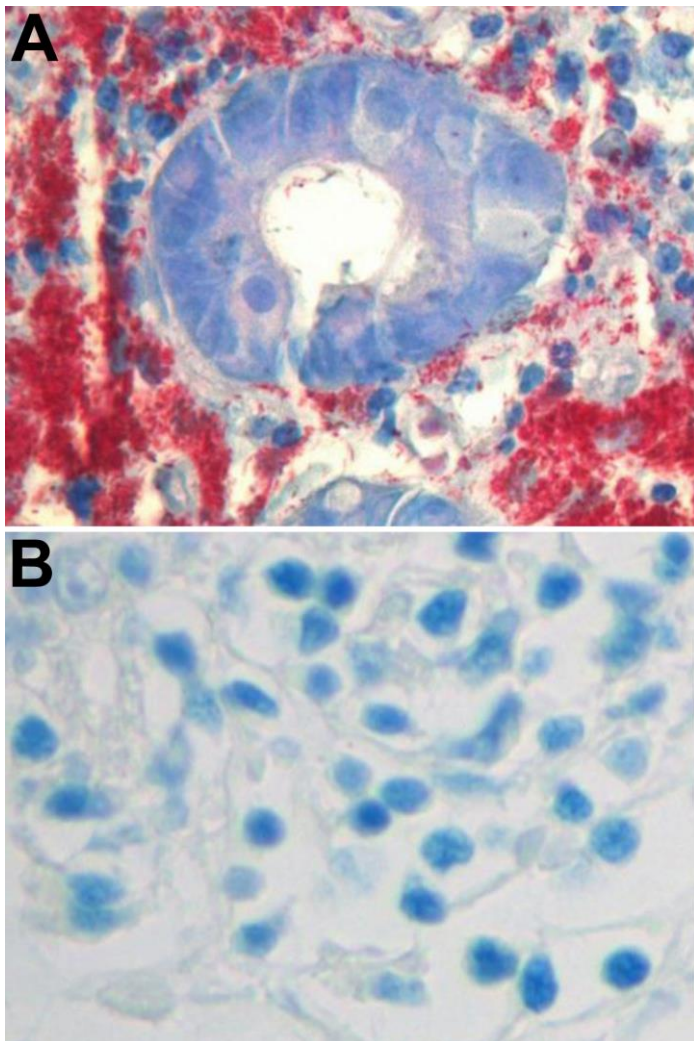
DOI: <http://dx.doi.org/10.3201/eid2109.150520>

**To the Editor:** *Corynebacterium bovis* is well known as a normal bovine microbiota and is a common cause of bovine mastitis (1). *C. bovis* infections in humans are rare, and identification of the organism by biochemical methods is challenging (2). Although 9 cases of *C. bovis* infections in humans have been reported (3–6), only the most recent case, which involved prosthetic joint infection, used 16S rRNA gene sequencing to identify the bacterium with certainty (6).

During February–July 2013, four adult patients (Table) were seen at Veterans Administration Puget Sound Health Care System in Seattle, Washington, USA, for eye swelling, pain, and purulent discharge. All 4 cases were

# Functional Immune Reconstitution by Therapy for HIV/Mycobacterial Co-infection

## Technical Appendix



Technical Appendix Figure. A) Abundant acid-fast bacilli on a stained histological specimen of a duodenal biopsy before the initiation of adjunctive interleukin-2 (IL-2) immunotherapy in an HIV-infected patient with disseminated *Mycobacterium tuberculosis* infection. B) Absence of acid-fast bacilli on a stained histological specimen of a duodenal biopsy after successful adjunctive IL-2 immunotherapy.