
Emergence of Thelaziosis Caused by *Thelazia callipaeda* in Dogs and Cats, United States

Ranju R.S. Manoj, Holly White, Rebecca Young, Charles E. Brown,
Renee Wilcox, Domenico Otranto, Manigandan Lejeune

We report 2 autochthonous feline thelaziosis cases caused by the eyeworm *Thelazia callipaeda* and discuss the spread among dogs in the northeastern United States. Phylogenetic analysis suggests the parasite was introduced from Europe. Adopting a One Health approach is needed to limit further spread of *T. callipaeda* eyeworms in North America.

Thelazia callipaeda eyeworm was considered an exotic parasite in North America until an autochthonous case was reported in a dog from New York, USA, in 2020 (1). *T. callipaeda* eyeworm has been reported in countries in East Asia and the Soviet Union, later expanding its geographic range into Europe (2,3). This zoonotic parasite primarily infects the orbital cavity of its host causing thelaziosis (3). The zoophilic secretophagous male fly, *Phortica variegata*, is a *T. callipaeda* vector; flies ingest first-stage *T. callipaeda* larvae from the lacrimal secretions of an infected host and redeposit them as infective third-stage larvae, which eventually complete their life cycle by developing into adult worms (4). *P. variegata* flies have been found in Orange and Monroe Counties in New York (5,6), which has likely promoted the emergence of *T. callipaeda* eyeworm in North America (4). Since the *T. callipaeda* infection in a dog reported in New York in 2020, a total of 11 canine cases (6 in New York, 3 in New Jersey, 1 each in Connecticut and Nevada) and 2 feline cases (both from New York) (Figure 1) have been confirmed morphologically at the Cornell Animal Health

Diagnostic Center (AHDC) in Ithaca, New York, USA. We describe 2 feline thelaziosis cases and discuss new canine cases in northeastern United States (New York/New Jersey border) during February 2021–December 2022 and One Health approaches to limit spread of this emerging disease in the United States.

The Study

Case 1 was in a 16-year-old neutered male, domestic shorthair cat from Greenwood Lake, Orange County, New York, that had been regularly cared for at the Warwick Valley Veterinary Hospital in New York, since October 2019. The animal had a recurrent history of flea infestation, which was managed with selamectin. The cat received routine rabies vaccinations at the clinic and was regularly dewormed with a combination of emodepside (3 mg/kg) and praziquantel (12 mg/kg) applied topically to the skin by the owner. Since June 2021, the animal has been treated for progressive chronic kidney disease. During a visit in April 2022, the cat had crusty lesions on its swollen right eye. Initial treatment with an ophthalmic ointment containing tobramycin resolved the eye infection. In August 2022, the cat manifested squinting, epiphora, and mucus accumulation in the right eye, which did not improve after tobramycin treatment. Detailed examination of the right eye revealed a constricted pupil and an elevated nictitating membrane with 4 thread-like worms, which were recovered mechanically at the clinic by flushing with saline solution. Of the 4 worms collected, 1 intact worm was received at AHDC for identification. The cat did not travel outside of New York. The animal was prescribed an ophthalmic ointment containing neomycin and polymyxin B and a dewormer (combination of emodepside [3 mg/kg] and praziquantel [12 mg/kg]) applied topically to the skin. No relapse was observed after treatment.

Author affiliations: Cornell University, Ithaca, New York, USA (R.R.S. Manoj, H. White, R. Young, M. Lejeune); Warwick Valley Veterinary Hospital, Warwick, New York, USA (C.E. Brown); Countryside Animal Hospital, Staatsburg, New York, USA (R. Wilcox); University of Bari Aldo Moro, Bari, Italy (D. Otranto); City University of Hong Kong, Hong Kong, China (D. Otranto)

DOI: <https://doi.org/10.3201/eid3003.230700>

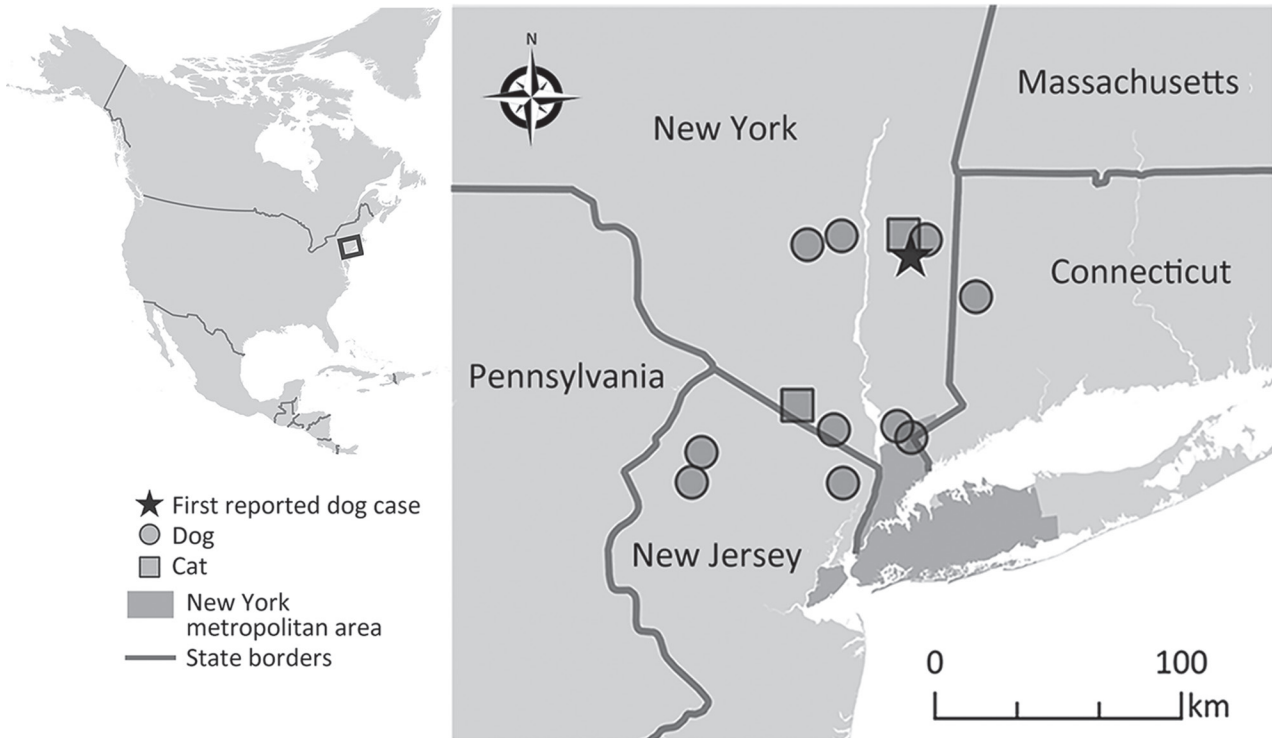


Figure 1. Locations of thelaziosis cases caused by *Thelazia callipaeda* eyeworm in dogs (circles) and cats (squares), New York, New Jersey, and Connecticut, USA. Star indicates the dog case reported in New York in 2020. Inset map indicates the area where *T. callipaeda* infections were reported (box). The dog case reported from Nevada was not included in the map because the travel history for that animal was unknown.

Case 2 was in a 2.5-year-old spayed female, domestic shorthair cat from a multicat household in Clinton Corners, Dutchess County, New York (adopted in Columbia County, New York). The cat did not travel outside of New York and was examined in October 2022 at a pet hospital during a routine rabies vaccination appointment. Ophthalmic examination revealed multiple white thread-like worms on the bulbar conjunctiva of both eyes (Figure 2). The cat had no clinical signs and was prescribed a dewormer (combination of emodepside [3 mg/kg] and praziquantel [12 mg/kg]) applied topically to the skin. Follow-up after 2 weeks revealed the presence of 8 worms, which were manually removed under local anesthesia. Two intact worms were sent to AHDC for identification. The cat was prescribed a combination of imidacloprid (10 mg/kg) and moxidectin (1 mg/kg) applied topically to the skin. Complete recovery was noted during a follow-up visit in November 2022.

At AHDC, we identified 1 male worm from case 1 and 2 female worms from case 2 morphologically as *T. callipaeda* eyeworm, primarily on the basis of transverse cuticular striations. The female worms were 11 and 14 mm long, and the male worm was 8.1 mm

long; all 3 had a wide, moderately deep buccal cavity. The number of transverse cuticular striations at the cephalic, midbody, and caudal regions ranged 150–400/mm/region in both male and female worms. In the male worm, the long spicule was ≈ 2 mm long

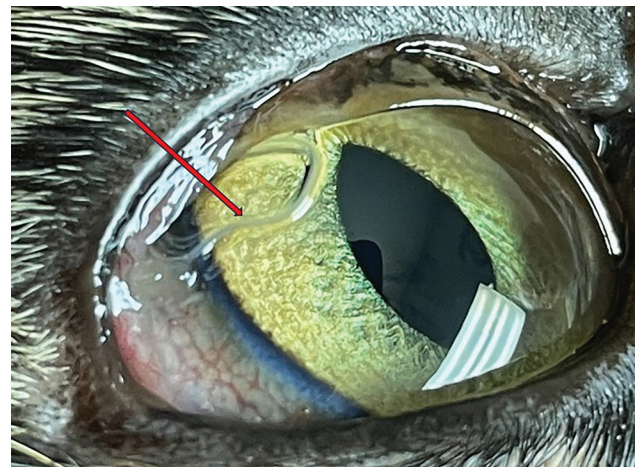


Figure 2. Adult parasites (red arrow) in the bulbar conjunctiva of the left eye of a cat in study of emergence of thelaziosis caused by *Thelazia callipaeda* in dogs and cats, United States. The cat was 2.5-year-old spayed female domestic shorthair cat (case 2) examined in October 2022.

and the short spicule was 0.1 mm long. The vulval opening in the female worms was anterior to the esophageal/intestinal junction (Appendix Figure 1, <https://wwwnc.cdc.gov/EID/article/30/3/23-0700-App1.pdf>).

We performed PCR on 1 female worm sample from feline case 2 and 1 sample from a dog case targeting 12S rRNA, 18S rRNA, and cytochrome oxidase c subunit 1 (*cox1*) using previously described protocols (7–9). The amplified PCR products for both worm samples were 421 bp for 12S rRNA, 891 bp for 18S rRNA, and 612 bp for *cox1*. We Sanger sequenced the PCR products, edited and aligned the sequences by using BioEdit (<https://bioedit.software.informer.com>), and compared them with available GenBank sequences by using BLAST analysis (<https://blast.ncbi.nlm.nih.gov>). We observed 100% sequence identity with corresponding genes available for *T. callipaeda* in GenBank. We deposited the sequences from this study in GenBank under accession nos. OR545549, OR545261, and OR982681. Phylogenetic analysis of the *cox1* sequences revealed clustering as a monophyletic clade with *T. callipaeda* haplotype 1 from Europe (10,11) (Appendix Figure 2). This study and the previous report on a dog (1) reconfirm the possibility that this parasite was introduced from Europe and subsequently spread in the United States.

Conclusions

The presence of *T. callipaeda* eyeworm in 2 cats and 11 dogs with no travel history outside of the United States suggests that this parasite is emerging in North America. Indeed, a previous study documented the presence of *P. variegata* flies in 2 counties in New York and indicated this fly species is a competent vector for *T. callipaeda* eyeworm, further suggesting an emerging threat by this eyeworm in the northeastern region of the United States (6). In addition, a wide variety of wildlife in New York, including coyotes, red foxes, gray foxes, black bears, raccoons, minks, least weasels, striped skunks, cottontail rabbits, and snowshoe hares, might act as potential hosts for *T. callipaeda* eyeworm (6); no human cases have been reported from this geographic area. A canine thelaziosis case was also found in the western United States (Nevada), although the travel history is unknown for that dog. Adopting proper diagnosis and surveillance measures is critical to limit the spread of this zoonotic parasite. Studies on control and treatment approaches for dogs suggest mechanical removal of adult and larval *T. callipaeda* nematodes coupled with the administration of diverse deworming drugs is effective (12). Because vector control using fly repellents

is ineffective (3), control of *T. callipaeda* infections mainly rely on diagnosis and timely anthelmintic treatment. The presence of the natural vector, *P. variegata* flies (4,6), and the potential involvement of the sylvatic cycle promote the spread of this exotic parasite. Most cases in this study were diagnosed in late summer and autumn, which correlates with peak fly activity. Therefore, prophylactic anthelmintic administration coinciding with fly seasons would be an effective control strategy. Furthermore, as indicated in previous reports (1,4), adoption of a holistic One Health approach will be effective in further limiting the spread of *T. callipaeda* eyeworm in North America.

Acknowledgments

We thank Nicholas A. Hollingshead for his assistance in preparing the map and Antech Diagnostics for sharing information about *Thelazia* infection cases.

About the Author

Dr. Manoj is a postdoctoral associate and Merck parasitology resident at the National Center for Veterinary Parasitology at the Animal Health Diagnostic Center, Cornell University, New York. Her research interests include vectorborne zoonotic diseases, particularly filarioids and their endosymbiont *Wolbachia*.

References

- Schwartz AB, Lejeune M, Verocai GG, Young R, Schwartz PH. Autochthonous *Thelazia callipaeda* infection in dog, New York, USA, 2020. *Emerg Infect Dis*. 2021;27:1923–6. <https://doi.org/10.3201/eid2707.210019>
- do Vale B, Lopes AP, da Conceição Fontes M, Silvestre M, Cardoso L, Coelho AC. Systematic review on infection and disease caused by *Thelazia callipaeda* in Europe: 2001–2020. *Parasite*. 2020;27:52. <https://doi.org/10.1051/parasite/2020048>
- Otranto D, Mendoza-Roldan JA, Dantas-Torres F. *Thelazia callipaeda*. *Trends Parasitol*. 2021;37:263–4. <https://doi.org/10.1016/j.pt.2020.04.013>
- Otranto D, Cantacessi C, Testini G, Lia RP. *Phortica variegata* as an intermediate host of *Thelazia callipaeda* under natural conditions: evidence for pathogen transmission by a male arthropod vector. *Int J Parasitol*. 2006;36:1167–73. <https://doi.org/10.1016/j.ijpara.2006.06.006>
- Werner T, Steenwinkel T, Jaenike J. The encyclopedia of North American drosophilids: drosophilids of the midwest and northeast. 2018 [cited 2021 May 10]. <https://digitalcommons.mtu.edu/cgi/viewcontent.cgi?article=1000&context=oabooks>
- Otranto D, Iatta R, Lia RP, Cavalera MA, Mâca J, Pombi M, et al. Competence of *Phortica variegata* from the United States as an intermediate host of the *Thelazia callipaeda* eyeworm. *Am J Trop Med Hyg*. 2018;98:1175–8. <https://doi.org/10.4269/ajtmh.17-0956>
- Floyd RM, Rogers AD, Lambshead PJD, Smith CR. Nematode-specific PCR primers for the 18S small subunit rRNA gene. *Mol Ecol Notes*. 2005;5:611–2. <https://doi.org/10.1111/j.1471-8286.2005.01009.x>


8. Casiraghi M, Anderson TJ, Bandi C, Bazzocchi C, Genchi C. A phylogenetic analysis of filarial nematodes: comparison with the phylogeny of *Wolbachia* endosymbionts. *Parasitology*. 2001;122:93–103. <https://doi.org/10.1017/S0031182000007149>
9. Morales-Hojas R, Cheke RA, Post RJ. Molecular systematics of five *Onchocerca* species (Nematoda: Filarioidea) including the human parasite, *O. volvulus*, suggest sympatric speciation. *J Helminthol*. 2006;80:281–90.
10. Tamura K, Stecher G, Kumar S. MEGA11: molecular evolutionary genetics analysis version 11. *Mol Biol Evol*. 2021;38:3022–7. <https://doi.org/10.1093/molbev/msab120>
11. Hasegawa M, Kishino H, Yano T. Dating of the human-ape splitting by a molecular clock of mitochondrial DNA. *J Mol Evol*. 1985;22:160–74. <https://doi.org/10.1007/BF02101694>
12. Bezerra-Santos MA, Mendoza-Roldan JA, Sgroi G, Lia RP, Venegoni G, Solari Basano F, et al. Efficacy of a formulation of sarolaner/moxidectin/pyrantel (Simparica Trio®) for the prevention of *Thelazia callipaeda* canine eyeworm infection. *Parasit Vectors*. 2022;15:370. <https://doi.org/10.1186/s13071-022-05501-6>

Address for correspondence: Manigandan Lejeune, Department of Population Medicine and Diagnostic Sciences, Cornell University College of Veterinary Medicine, Ithaca, NY 14853, USA; email: ml872@cornell.edu

January 2023

Vectorborne Infections

- Comprehensive Review of Emergence and Virology of Tickborne Bourbon Virus in the United States
- Multicenter Case–Control Study of COVID-19–Associated Mucormycosis Outbreak, India
- Risk for Severe Illness and Death among Pediatric Patients with Down Syndrome Hospitalized for COVID-19, Brazil
- Molecular Tools for Early Detection of Invasive Malaria Vector *Anopheles stephensi* Mosquitoes
- Integrating Citizen Scientist Data into the Surveillance System for Avian Influenza Virus, Taiwan
- Widespread Exposure to Mosquitoborne California Serogroup Viruses in Caribou, Arctic Fox, Red Fox, and Polar Bears, Canada
- Genomic Confirmation of *Borrelia garinii*, United States
- Seroepidemiology and Carriage of Diphtheria in Epidemic-Prone Area and Implications for Vaccination Policy, Vietnam
- *Akkermansia muciniphila* Associated with Improved Linear Growth among Young Children, Democratic Republic of the Congo
- High SARS-CoV-2 Seroprevalence after Second COVID-19 Wave (October 2020–April 2021), Democratic Republic of the Congo
- Human Immunity and Susceptibility to Influenza A(H3) Viruses of Avian, Equine, and Swine Origin



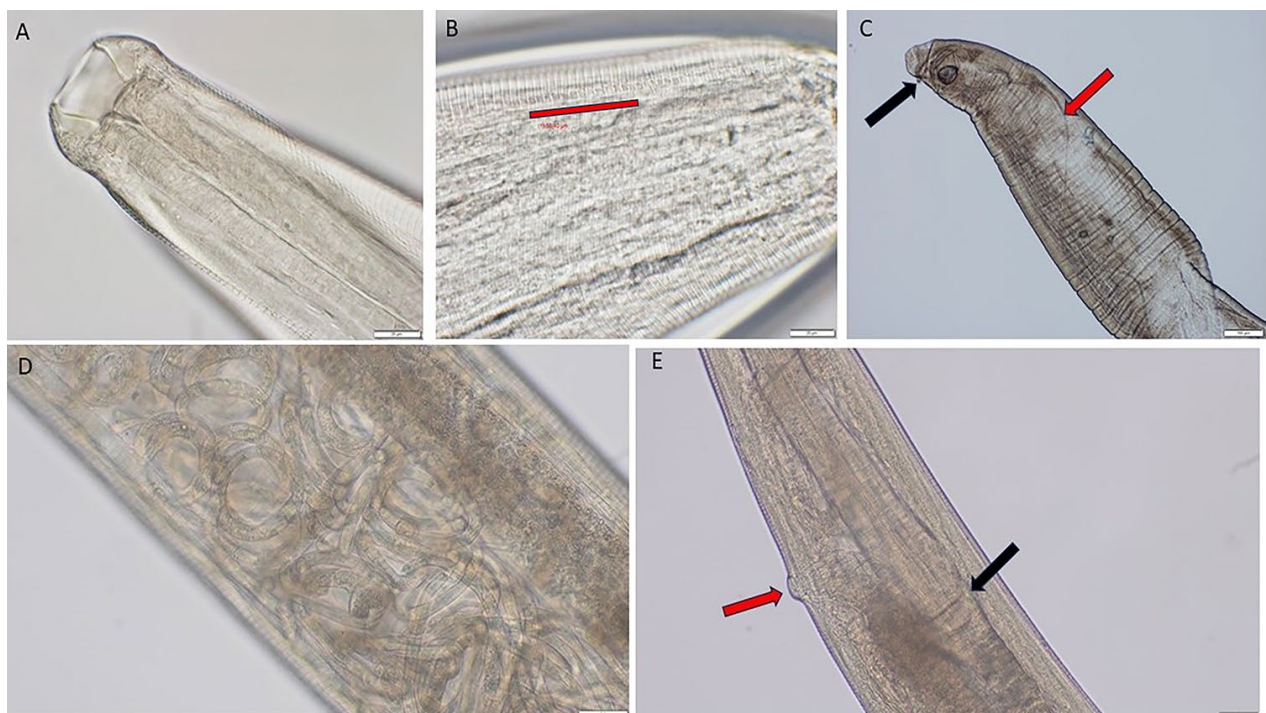
- Role of Seaports and Imported Rats in Seoul Hantavirus Circulation, Africa
- *Plasmodium falciparum* *pfhrp2* and *pfhrp3* Gene Deletions in Malaria-Hyperendemic Region, South Sudan
- Burden of Postinfectious Symptoms after Acute Dengue, Vietnam
- Survey of West Nile and Banzi Viruses in Mosquitoes, South Africa, 2011–2018
- Detection of Clade 2.3.4.4b Avian Influenza A(H5N8) Virus in Cambodia, 2021
- Using Serum Specimens for Real-Time PCR-Based Diagnosis of Human Granulocytic Anaplasmosis, Canada
- *Photobacterium damsela* subspecies *damsela* Pneumonia in Dead, Stranded Bottlenose Dolphin, Eastern Mediterranean Sea
- Efficient Inactivation of Monkeypox Virus by World Health Organization–Recommended Hand Rub Formulations and Alcohols
- Detection of Monkeypox Virus DNA in Airport Wastewater, Rome, Italy
- Successful Treatment of *Balamuthia mandrillaris* Granulomatous Amebic Encephalitis with Nitroxoline
- Clinical Forms of Japanese Spotted Fever from Case-Series Study, Zigui County, Hubei Province, China, 2021
- COVID-19 Symptoms by Variant Period in the North Carolina COVID-19 Community Research Partnership, North Carolina, USA
- Increased Seroprevalence of Typhus Group Rickettsiosis, Galveston County, Texas, USA
- Genomic Epidemiology Linking Nonendemic Coccidioidomycosis to Travel
- Risk for Severe COVID-19 Outcomes among Persons with Intellectual Disabilities, the Netherlands
- Effects of Second Dose of SARS-CoV-2 Vaccination on Household Transmission, England
- COVID-19 Booster Dose Vaccination Coverage and Factors Associated with Booster Vaccination among Adults, United States, March 2022
- Pathologic and Immunohistochemical Evidence of Possible Francisellaceae among Aborted Ovine Fetuses, Uruguay
- Bourbon Virus Transmission, New York, USA
- Genomic Microevolution of *Vibrio cholerae* O1, Lake Tanganyika Basin, Africa

**EMERGING
INFECTIOUS DISEASES**

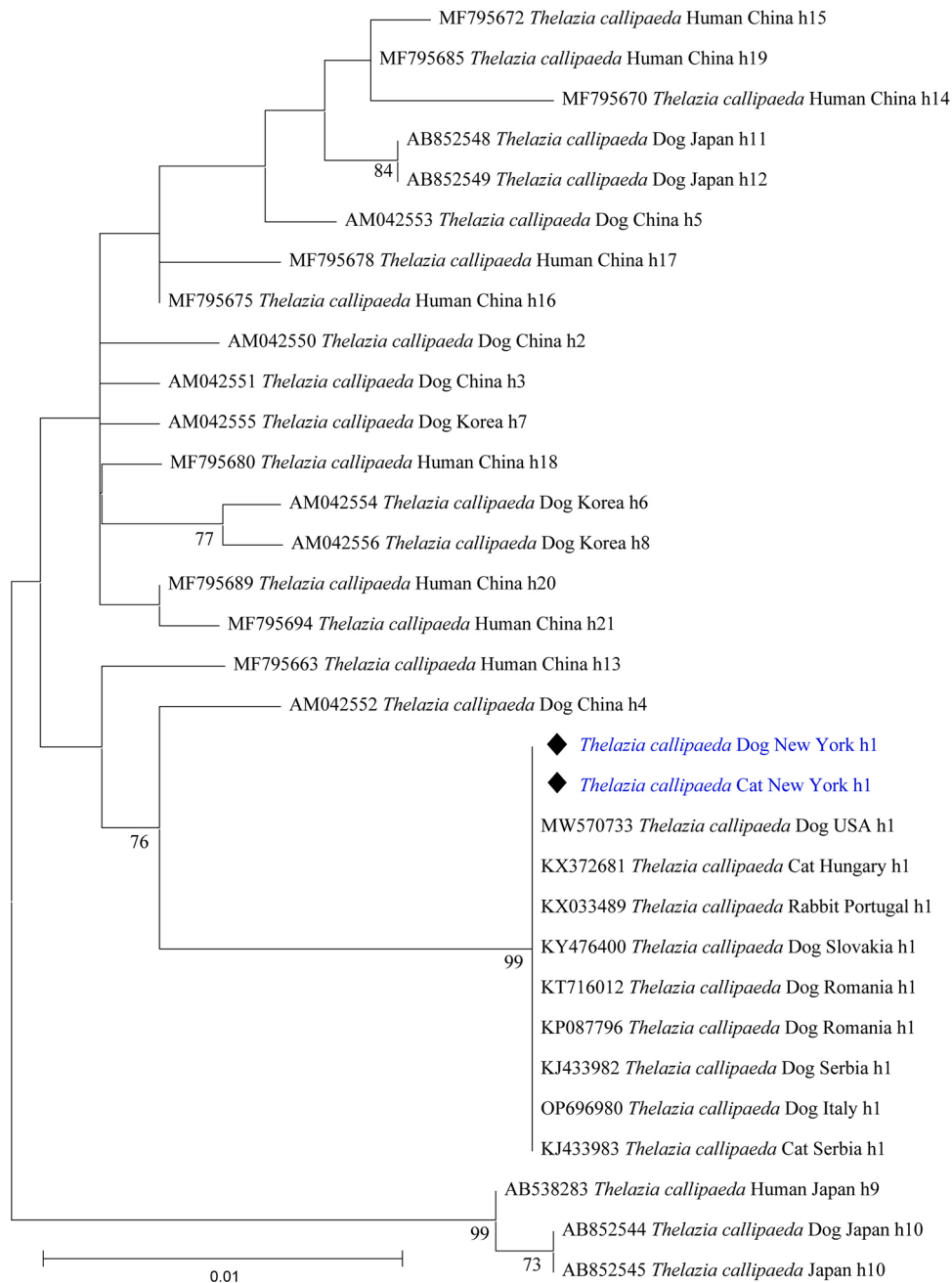
To revisit the January 2023 issue, go to:
<https://wwwnc.cdc.gov/eid/articles/issue/29/1/table-of-contents>

Emergence of Thelaziosis Caused by *Thelazia callipaeda* in Dogs and Cats, United States

Appendix



Appendix Figure 1. Morphologic identification of *Thelazia callipaeda*. Specimens were examined under an Olympus compound microscope (BX53) (Olympus, <https://www.olympus-lifescience.com>), and images were captured with an Olympus DP73 camera. Morphometry was performed with Olympus cellSens software. A) Cephalic end of female worm with a wide, moderately deep buccal cavity. Original magnification $\times 200$. B) Prominent tightly spaced cuticular striations. Red line indicates 50 μm . Original magnification $\times 200$. C) Caudal end of male worm. Red arrow indicates long spicule; black arrow indicates short spicule. Original magnification $\times 100$. D) Uterus of adult worm showing L1 (first) stage of parasite larvae. Original magnification $\times 500$. E) Vulval opening at the esophageal region. Black arrow indicates the esophageal/intestinal junction; red arrow indicates the vulval opening. Original magnification $\times 100$.



Appendix Figure 2. Phylogenetic analysis of the partial *cox1* gene sequence of *Thelazia callipaeda* detected in this study compared with other *T. callipaeda* haplotypes from GenBank. Analysis was conducted in MEGA11 (10, main text) by using the maximum-likelihood method (1,000 bootstrap replications) and the Hasegawa-Kishino-Yano model (11, main text). A discrete gamma distribution was used to model evolutionary rate differences among sites. Sequences from this study are highlighted in blue. Scale bar indicates nucleotide substitutions per site.