

- 2015;32:268–74. <https://doi.org/10.1093/molbev/msu300>
7. Beckert P, Sanchez-Padilla E, Merker M, Dreyer V, Kohl TA, Utpatel C, et al. MDR M. tuberculosis outbreak clone in Eswatini missed by Xpert has elevated bedaquiline resistance dated to the pre-treatment era. *Genome Med.* 2020;12:104. <https://doi.org/10.1186/s13073-020-00793-8>
  8. Zetola NM, Moonan PK, Click E, Oeltmann JE, Basotli J, Wen X-J, et al. Population-based geospatial and molecular epidemiologic study of tuberculosis transmission dynamics, Botswana, 2012–2016. *Emerg Infect Dis.* 2021;27:835–44. <https://doi.org/10.3201/eid2703.203840>
  9. World Health Organization. Use of targeted next-generation sequencing to detect drug-resistant tuberculosis [cited 2023 Aug 22]. <https://www.who.int/publications/i/item/9789240076372>
  10. Thornton J. Botswana's HIV/AIDS success. *Lancet.* 2022; 400:480–1. [https://doi.org/10.1016/S0140-6736\(22\)01523-9](https://doi.org/10.1016/S0140-6736(22)01523-9)

Address for correspondence: Sanghyuk S. Shin, Sue and Bill Gross School of Nursing, UCI Infectious Disease Science Initiative, University of California, Irvine, 854 Health Science Quad, Irvine, CA 92697 USA; email: ssshin2@uci.edu

## Scedosporium Infection in Recipients of Kidney Transplants from Deceased Near-Drowning Donor

Devprakash Choudhary, Harsimran Kaur, Vanji Nathan Subramani, Smita Pattanaik, Shivakumar S. Patil, Jasmine Sethi, Manharpreet Kaur, Priya Sreenivasan, Sheetal Thakur, Parul Gupta, Arvind Sekar, Sarbpreet Singh, Muralidharan Jayashree, Deepesh Kenwar, Shivaprakash M. Rudramurthy, Ashish Sharma

Author affiliation: Postgraduate Institute of Medical Education and Research, Chandigarh, India

DOI: <https://doi.org/10.3201/eid2911.231000>

*Scedosporium aurianticum* infection developed in 2 recipients of kidney transplants in India, acquired from the same deceased near-drowning donor. Given the substantial risk for death associated with *Scedosporium* infection among solid-organ transplant recipients, safety protocols for organ transplantation from nearly drowned donors should be thoroughly reevaluated and refined.

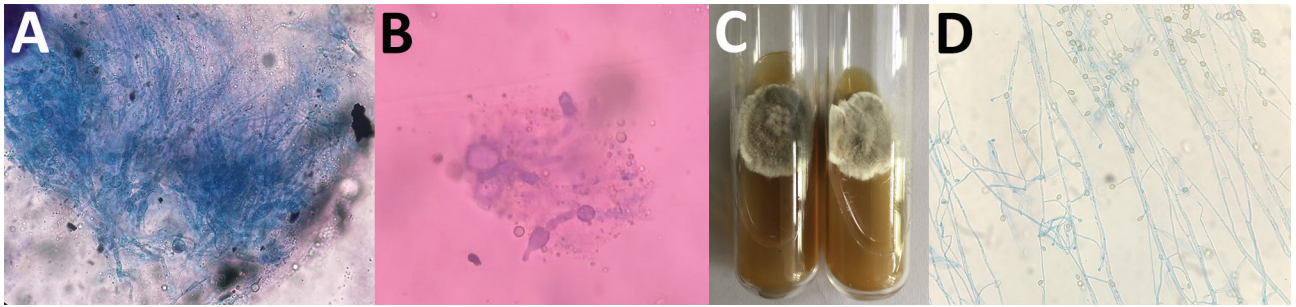
Drowning causes 236,000 deaths annually worldwide and is the third leading cause of accidental child death (1). Hospitalization from near-drowning occurs 2–20 times more frequently than fatal drownings (2). Near-drowning can result in *Scedosporium* spp. fungal infection, which causes pneumonia with a high mortality rate among nearly drowned children and young adults (2). Detecting *Scedosporium* in deceased persons is challenging, and infections thus often remain undetected. Because donor-derived *Scedosporium* infections (DDSI) from nearly drowned donors (NDD) have been linked to substantial allograft loss and increased risk for death among kidney transplant recipients (3–6), undetected *Scedosporium* poses a substantial concern when considering that person for organ donation.

We report on 2 kidney transplant recipients from an NDD, probably infected with *Scedosporium aurianticum*. The Postgraduate Institute of Medical Education and Research ethics committee approved the study. We obtained informed consent from both case-patients to ensure understanding and voluntary participation.

A 2-year-old girl weighing 15 kg was admitted to hospital with hypoxic ischemic encephalopathy and respiratory distress after a nonfatal near-drowning experience in a water tank. Her fever persisted despite antimicrobial treatment for suspected pneumonia but resolved after subsequent liposomal amphotericin B therapy. The girl was declared brain dead after 2 weeks of hospitalization, and her kidneys were retrieved for transplantation (Appendix, <https://wwwnc.cdc.gov/EID/article/29/11/23-1000-App1.pdf>).

Recipient 1, a 42-year-old woman, received 1 kidney from the deceased NDD. However, 10 days after the procedure, thrombosis developed in the graft renal artery, necessitating a graft nephrectomy. The allograft exhibited septate fungal hyphae, and grew *Scedosporium* on culture (Figure). She received a 6-month course of voriconazole and remained symptom-free on hemodialysis while awaiting a second transplant. (Appendix).

Recipient 2, a 23-year-old woman who received the other kidney from the same NDD, developed high-grade fever 3 days after transplantation. We suspected fungal infection on the basis of high  $\beta$ -D-glucan despite sterile blood cultures and initiated liposomal amphotericin B therapy. However, after we identified *S. aurianticum* infection in the first recipient, we switched the second patient's treatment to voriconazole. We briefly halted voriconazole therapy because of a period of elevated liver enzymes, during which the patient experienced occasional headaches and swelling developed in her left leg. The aspirate from the swelling revealed



**Figure.** Testing for *Scedosporium aurianticum* infection in 2 recipients of kidney transplants from deceased near-drowning donor, India. A, B) Potassium hydroxide mount of renal allograft tissue from transplant recipient 1 (A) and skin biopsy from transplant recipient 2 (B) showing septate hyphae. C) Culture on Sabouraud dextrose agar showing a greyish-white colony of *S. aurianticum* from recipients 1 (left) and 2 (right) D) Lactophenol cotton blue mount from a culture from recipient 1 showing smooth-walled sessile conidia on cylindrical or flask-shaped conidiogenous cells.

*S. aurianticum* mold (Figure), and amplified fragment-length polymorphism molecular typing (Appendix Figure 2) suggested a likely acquisition by kidney donor. After recipient 2 resumed voriconazole therapy, her swelling resolved, and she remained well with stable graft function 12 months after the kidney transplant (Appendix Figure 1).

Donor-derived infection occurs in 0.2%–1.7% of solid organ transplant recipients (7). However, because of the unique characteristics of drowning, ubiquitous fungi of genus *Scedosporium* can permeate the donor's respiratory system, increasing risk of transmission to transplant recipients. We searched transplant literature for additional accounts of probable DDSI cases on the basis of the uniform definition of donor-derived infections from a NDD (7). DDSI from NDD poses an unusually heightened risk of death among solid organ transplant recipients (3–6). Consequently, transplant centers remain cautious about considering organs from NDDs (8).

*Scedosporium* has emerged as the predominant fungal pathogen causing pneumonia after near-drowning events (2). The International Society for Human and Animal Mycology (<https://www.ish-am.org>) recently introduced a distinct category for fatal cerebral infections after near-drowning incidents linked to *Scedosporium*, which has been documented to precipitate potentially fatal disseminated infections in 70% of immunocompetent and 100% of immunocompromised hosts (9). Addressing *Scedosporium* infection is particularly challenging because of its inherent antifungal resistance, propensity for rapid spread (notably from the lungs to the central nervous system), limited sensitivity of culture based methods, and relatively slow growth of cultured isolates compared to other common saprophytic molds. Those factors collectively lead to delayed diagnoses,

elevated therapeutic failures, and increased relapse rates (10).

The risk of infection transmission during drowning events is influenced by several factors, including the type of drowning. Dry drowning, in which the airways close due to spasms without fluid inhalation to the lungs, often results in better outcomes compared with other types. Water temperature also plays a role; cooler temperatures are often linked to more favorable results. Other considerations affecting risk include volume of aspirated water; occurrence of gastric aspiration, which can harm pulmonary epithelial barriers; and specifics of the drowning location, such as water depth, with shallow water presenting a higher risk (2,8).

Although the Disease Transmission Advisory Committee of the Organ Procurement and Transplant Network/United Network for Organ Sharing (<https://unos.org>) has been operational for more than a decade, specific risk factors for DDSI transmission from NDDs have not yet been defined. The passive reporting system used by the Disease Transmission Advisory Committee and frequent omissions of crucial NDD data in donor medical records impede comprehensive understanding of DDSI transmission risks (7). Furthermore, identifying DDSI from NDDs before transmission poses substantial challenges, such as selecting effective and accurate detection methods and determining the samples needed for testing and optimal time for collection.

Routine PCR screening of organs from NDDs for fungi would ensure accurate identification, timely detection, prompt management, and well-informed decision-making. In addition, uniform international guidelines regarding use of organs from NDDs are needed to address critical technical and procedural issues essential for mitigating risk for DDSI transmission.

## About the Author

Dr. Choudhary is a distinguished alumnus of PGIMER Chandigarh's Renal Transplant Surgery Department. His primary interests include integrating a holistic, patient-centered philosophy into patient care in transplantation medicine.

## References

1. United Nations. World Drowning Prevention Day [cited 2023 Sep 16]. <https://www.un.org/en/observances/drowning-prevention-day>
2. Katragkou A, Dotis J, Kotsiou M, Tamiolaki M, Roilides E. *Scedosporium apiospermum* infection after near-drowning. *Mycoses*. 2007;50:412-21. <https://doi.org/10.1111/j.1439-0507.2007.01388.x>
3. Wu K, Annambhotla P, Free RJ, Ritter JM, Leitgeb B, Jackson BR, et al. Fatal invasive mold infections after transplantation of organs recovered from drowned donors, United States, 2011-2021. *Emerg Infect Dis*. 2023;29:1455-8.
4. Kim SH, Ha YE, Youn JC, Park JS, Sung H, Kim MN, et al. Fatal scedosporiosis in multiple solid organ allografts transmitted from a nearly-drowned donor. *Am J Transplant*. 2015;15:833-40. <https://doi.org/10.1111/ajt.13008>
5. van der Vliet JA, Tidow G, Kootstra G, van Saene HFK, Krom RAF, Sloof MJ, et al. Transplantation of contaminated organs. *Br J Surg*. 1980;67:596-8. <https://doi.org/10.1002/bjs.1800670822>
6. Leek R, Aldag E, Nadeem I, Gunabushanam V, Sahajpal A, Kramer DJ, et al. Scedosporiosis in a combined kidney and liver transplant recipient: a case report of possible transmission from a near-drowning donor. *Case Rep Transplant*. 2016;2016:1879529. <https://doi.org/10.1155/2016/1879529>
7. Wolfe CR, Ison MG; AST Infectious Diseases Community of Practice. Donor-derived infections: guidelines from the American Society of Transplantation Infectious Diseases Community of Practice. *Clin Transplant*. 2019;33:e13547. <https://doi.org/10.1111/ctr.13547>
8. Pasupneti S, Patel K, Mooney JJ, Chhatwani L, Dhillon G, Weill D. Lung transplantation following death by drowning: a review of the current literature. *Clin Transplant*. 2016;30:1195-7. <https://doi.org/10.1111/ctr.12822>
9. Ramirez-Garcia A, Pellon A, Rementeria A, Buldain I, Barreto-Bergter E, Rollin-Pinheiro R, et al. *Scedosporium* and *Lomentospora*: an updated overview of underrated opportunists. *Med Mycol*. 2018;56(suppl\_1):102-25. <https://doi.org/10.1093/mmy/myx113>
10. Hoenigl M, Salmanton-García J, Walsh TJ, Nucci M, Neoh CF, Jenks JD, et al. Global guideline for the diagnosis and management of rare mould infections: an initiative of the European Confederation of Medical Mycology in cooperation with the International Society for Human and Animal Mycology and the American Society for Microbiology. *Lancet Infect Dis*. 2021;21:e246-57. [https://doi.org/10.1016/S1473-3099\(20\)30784-2](https://doi.org/10.1016/S1473-3099(20)30784-2)

---

Address for correspondence: Shivaprakash M. Rudramurthy, WHO Collaborating Center and Center of Advanced Research in Medical Mycology, National Culture Collection of Pathogenic Fungi, Department of Medical Microbiology, Postgraduate Institute of Medical Education and Research, Chandigarh 160012, India; email: mrshivprakash@yahoo.com, mrshivprakash@gmail.com; Shivakumar S. Patil, Department of Renal Transplant Surgery, Postgraduate Institute of Medical Education and Research, Chandigarh 160012, India; email: drshivpgi@gmail.com

# *Scedosporium* Infection in Recipients of Kidney Transplants from Deceased Near-Drowning Donor

## **Appendix**

### **Deceased Donor Clinical Parameters**

Donor presented with compensated shock with normal CT head. Meropenem and vancomycin were initiated to treat possible polymicrobial infections. Persistent fever(39.5-40°C) on day-five of admission which resolved after starting LAMB. Over two-weeks, her bronchoalveolar lavage, blood, and urine cultures remained sterile with fluctuating leucocyte (3,100-11,160/mm<sup>3</sup>), and norepinephrine (0.1mcg/kg/min) was required to achieve mean arterial pressure>50th-centile. Day-11 CT-head showed cerebral edema, and brain death was declared on day-14. Only kidneys were retrieved.

### **Kidney Transplant Recipient 1**

On maintenance hemodialysis for five year for endstage renal disease due to chronic glomerulonephritis underwent KT receiveing standard antimicrobial prophylaxis and immunosuppressive regimen. Within a week post-KT, KTR-1 creatinine decreased from 9 to 5.2 mg/dl. On day-10, anuria and absent graft blood flow led to graft-nephrectomy for renal-artery thrombosis. Post graft nephrectomy she was discharged with a normal MRI brain and sterile blood cultures. She continued hemodialysis and completed a six-month oral voriconazole(200mg BD) course, maintaining therapeutic levels 5-5.2µg/ml. Follow-up- Nine months

### **Kidney Transplant Recipient 2**

On maintenance hemodialysis for six year for endstage renal disease due to chronic glomerulonephritis underwent KT receiveing standard antimicrobial prophylaxis and immunosuppressive regimen. Three days post-KT, she developed persistent fever(38.5-39°C),

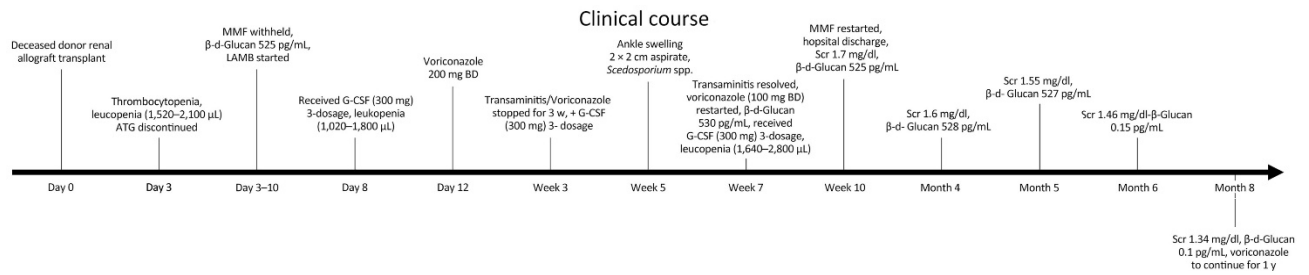
leukopenia(2,500 $\mu$ L), and thrombocytopenia(70,000 $\mu$ L). Her treatment was switched from LAMB to oral voriconazole(200 mgBD) when *Scedosporium* was identified in KTR-1. Voriconazole course was temporarily interrupted due to elevated liver enzymes, her blood cultures were sterile and brain imaging was normal. Two-months later, voriconazole was resumed at reduced dosage(100mg BD). At nine-month follow-up therapeutic voriconazole levels(4.2-4.5 $\mu$ g/ml) are maintained with a serum creatinine (SCr) level of 1.34mg/dl.

### **Immunosuppression Protocol Kidney Transplant Recipients 1 and 2**

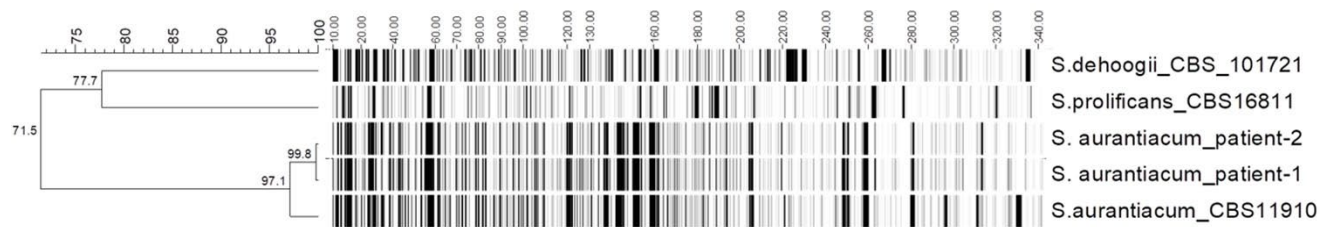Standard antimicrobial-prophylaxis (cefuroxime-1.5gm), intraoperative methylprednisolone (500mg), anti-thymocyte globulin (ATG-150mg X 3-days), and a standard triple-drug regimen of immunosuppressive (tacrolimus [5mgBD], mycophenolate-mofetil [1gmBD], and prednisolone [25mgOD])

### **Mycology**

The allograft of KTR-1 and leg-aspirate of KTR-2 exhibited septate fungal hyphae under calcofluor KOH wet-mount examination (Figure 1). Both samples cultured on Sabouraud dextrose-agar yielded greyish-brown molds at 25°C and 37°C, identified as *Scedosporium* spp based on smooth-walled sessile conidia on cylindrical or flask-shaped conidiogenous-cells (Figure 1). Further sequencing of the rDNA's internal transcribed spacer region confirmed the isolates as *Scedosporium aurianticum*. Both isolates showed a 100% match with the *S. aurianticum* FMR 8630 type culture and were submitted to GenBank (accession numbers OQ891109 and OQ891110). Amplified fragment length polymorphism (AFLP) typing indicated a 99% match between isolates (Appendix Figure 2), confirming common-donor origin. Both isolates have been stored in the National Culture Collection of Pathogenic Fungi, Chandigarh, India. Antifungal susceptibility testing per clinical and laboratory standards institute (CLSI, 2017) broth microdilution-technique (M38) displayed varying minimum inhibitory concentrations (MIC- $\mu$ g/ml): amphotericin B (4–8), voriconazole (0.06–0.12), itraconazole (4 each), Posaconazole (2 each), caspofungin (16 each), anidulafungin (4–8), and micafungin (8–16).



**Appendix Figure 1.** Clinical course of kidney transplant recipient 2.



**Appendix Figure 2.** Amplified fragment length polymorphism of isolates from both patients, *S. aurantiacum* CBS (Centraalbureau voor Schimmelcultures) 11910, *Lomentospora prolificans* CBS 16811, and *S. dehoogii* CBS 101721.