

Refractory *Microascus* Bronchopulmonary Infection Treated with Olorofim, France

Emmanuel Faure, Olivier Brugière, Sylvie Colin de Verdier, Fanny Vuotto, Lucie Limousin, Emilie Cardot, Camille Cordier, Pauline Coulon, Dea Garcia-Hermoso, Olivier Lortholary, Fanny Lanternier

Author affiliations: Université de Lille, Lille, France (E. Faure); Centre Hospitalier Régional Universitaire Lille, Lille (E. Faure, F. Vuotto, C. Cordier, P. Coulon); Hôpital Foch, Suresnes, France (O. Brugière, S. Colin de Verdier, L. Limousin, E. Cardot); Institut Pasteur, Paris, France (D. Garcia-Hermoso, O. Lortholary, F. Lanternier); University Hospital Necker for Sick Children, Assistance Publique-Hôpitaux de Paris, Paris (O. Lortholary, F. Lanternier)

DOI: <https://doi.org/10.3201/eid2911.230984>

We report 3 cases of successful treatment of *Microascus* spp. bronchopulmonary infection in a multiple-traumatized patient and 2 lung transplant recipients in France. We emphasize the promising use of olorofim antifungal therapy in a rising context of intrinsically less-susceptible respiratory infections caused by mold.

The family Microasaceae includes genera *Microascus* and *Scopulariopsis*, opportunistic fungi that have caused respiratory infection associated with poor outcome and an attributable mortality rate of 85%–100% (1,2). Treatment of invasive *Microascus* infection is challenging because of its high resistance to available therapies. Olorofim, a reversible inhibitor of the enzyme dihydroorotate dehydrogenase, has

shown in vitro activity against a variety of mold species, including azole-resistant *Aspergillus* (3,4) and *Microascus* spp. (5). We describe 3 cases of invasive *Microascus* respiratory infection in France that were treated with olorofim (Table). All patients gave informed consent for publication.

Case 1 occurred in a 17-year-old boy with unremarkable medical history who was found unconscious with inhalation pneumonia, bilateral hemothorax, and bilateral thoracic drainage after falling from the top of a rice silo (Appendix Figure 1, <https://wwwnc.cdc.gov/EID/article/29/11/23-0984-App1.pdf>). On day 2, the patient underwent venovenous extracorporeal membrane oxygenation. On day 38, after 5 weeks of adapted antimicrobial treatment, thoracic computed tomography (CT) scan showed worsening of bilateral necrotizing pneumonia with abscess. Bronchoalveolar lavage (BAL) and several bronchial aspirations grew a restricted light-gray fungal colony (Appendix Figure 2), identified through the Paris National Reference Center as compatible with *Microascus melanosporus*; we initiated a combination of olorofim (180 mg 2×/d on day 1, followed by 90 mg 2×/d) and terbinafine (500 mg 2×/d) for 6 weeks (Appendix Table). Radiologic findings and general clinical status improved; we discontinued oxygen support after 2 weeks (day 73). The last CT scan showed complete healing of lung lesions (day 120). The patient was still alive 1 year later.

Case 2 occurred in a 61-year-old lung transplant recipient who sought care for respiratory deterioration and decline in respiratory function. He had recently received isavuconazole for bronchial colonization with *Aspergillus flavus*. Thoracic CT scan at admission showed a new alveolar consolidation in the left upper lobe (Appendix Figure 3); fibroscopy showed a recent-onset yellowish irregular lesion in the culminal bronchus (Figure, panel A). We isolat-

Table. Medical history and keypoints of 3 case-patients with refractory microascus bronchopulmonary infection, France*

Characteristic	Case 1	Case 2	Case 3
Age, y	17	61	65
Immunocompromised status	No	Lung transplant	Lung transplant
Years since transplantation	NA	4	6
Chronic lung allograft dysfunction	NA	Y (for 2 y)	Y (for 5 y)
Intensification of immunosuppressive drug regimen in medical history	NA	Antithymocyte globulin, steroids, rituximab, alemtuzumab, extracorporeal photopheresis	Steroids, rituximab, bortezomib
Maintenance therapy on the onset of <i>Microascus</i> infection	NA	Tacrolimus (C ₀ 4-6 ng/mL), everolimus (C ₀ 4-6 ng/mL), prednisone (5 mg/d)	Tacrolimus (C ₀ 4-6 ng/mL), Everolimus (C ₀ 4-6 ng/mL), prednisone (5 mg/d)
Recent antifungal exposition <3 mo	None	Isavuconazole	Isavuconazole
Tolerance			
Clinical	No SSE	NA	No SSE
Biologic	No ELE	Drug interaction with tacrolimus and everolimus	No ELE

*ELE, elevated liver enzyme; NA, not applicable; SSE, significant side effect.

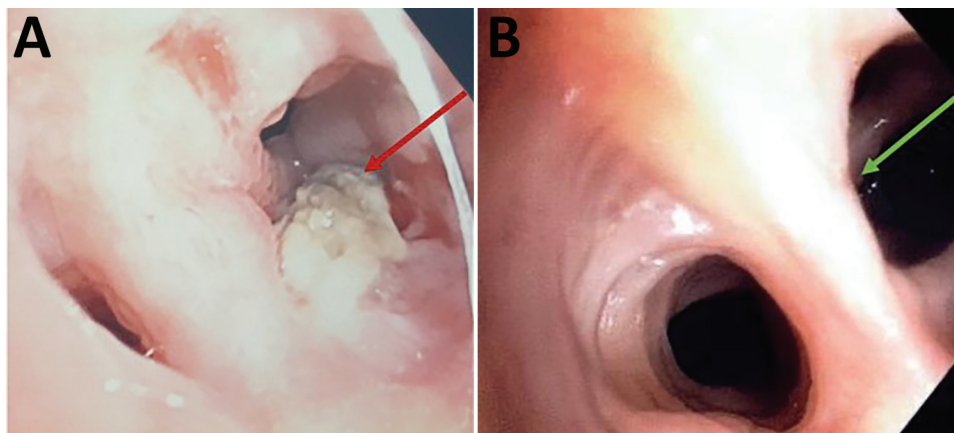


Figure. Macroscopic observation of endobronchial *Microascus cirrosus* lesion in patient in France with refractory microascus bronchopulmonary infection before (A) and after (B) orlofim treatment. Arrows indicate the lesion.

ed *M. cirrosus* from a culture of bronchial aspirate and BAL. We found no other disseminated lesions and retained the diagnosis of invasive pulmonary *M. cirrosus* infection. We initiated orlofim (90 mg 2×/d). We observed, as previously described (6), a moderate increase of both tacrolimus and everolimus blood through levels, which may have been caused by orlofim, a weak inhibitor of CYP 3A4. After 3 months of treatment, lung function slightly improved, CT scan showed a near-complete disappearance of the consolidation, and BAL culture was sterile. After 8 months of orlofim treatment, the endobronchial lesion was gone (Figure, panel B). *M. cirrosus* was found in BAL after 6 months of orlofim, but no more was cultured from BAL 7 months after treatment initiation. The patient was still being treated with orlofim at 9 months.

Case 3 occurred in a 65-year-old lung transplant recipient who sought care for dyspnea. He had experienced progressive decline of respiratory function and had a diagnosis of grade 3 bronchiolitis obliterative syndrome (BOS) linked to obstructive respiratory failure 6 years after transplant. He required permanent oxygen support. At admission, he received isavuconazole that continued for 3 months because of bronchial colonization with *A. fumigatus*. Thoracic CT scan results showed an unchanged pattern of BOS. Nevertheless, bronchial fibroscopy showed a new-onset bronchial lesion, necrotic and blackish in appearance, obstructing the origin of the culminal bronchus (Appendix Figure 4). We isolated *M. cirrosus* samples. Patient received a combination of oral terbinafine (500 mg 2×/d) and orlofim (180 mg 2×/d on day 1 followed by 90 mg 2×/d). After 3 months of treatment, bronchial fibroscopy showed an improvement of the bronchial lesion, and *M. cirrosus* was not found in respiratory specimens. The patient died from respiratory failure attributed to progression of BOS.

Use of orlofim for invasive *Microascus* spp. respiratory infection has not previously been reported with a successful outcome; previous studies were conducted in vitro (4). Miossec et al. (1) reported a series of 9 cases; all 9 patients had a medical history of stem cell or solid organ transplantation, and 8 died. The only survivor was a patient considered immunocompetent with no identified underlying conditions. A fatal *Microascus* sp. lung infection was previously published in a lung transplant recipient (6). Here, we report 2 lung transplant recipients infected with *M. cirrosus*, a ubiquitous mold isolated from soil and moist indoor environments (7). The third case we report was a young immunocompetent adult with no underlying conditions infected with *M. melanosporus*; his exposure by falling in a rice silo and sustaining serious injuries may explain the onset of opportunistic infection.

Microascus spp. and *Scopulariopsis* (8) exhibit a multidrug-resistant phenotype (9). Skóra et al. reported antifungal susceptibility results of several *Microascus* species and confirmed high resistance to ciclopirox, 5-fluorocytosine, amphotericin B, and azoles. However, among echinocandin, lower minimum effective concentrations for caspofungin were reported (10). The highest in vitro activity was observed with terbinafine (10); synergistic activity was observed against some *Scopulariopsis* strains (9). Wiederhold et al. reported promising activity of orlofim on *Scopulariopsis* spp. and *Microascus* spp. fungi (5), but no synergistic in vitro activity was reported between orlofim and terbinafine against *Microascus* spp.

Acknowledgments

We thank F2G laboratory (Manchester, UK) for providing orlofim for compassionate use after reviewing the medical history of the cases with O.L. and F.L.

Author contributions: E.F., O.B., and E.C. were involved in patient care. C.C., P.C., and L.L. were mycologists in charge of laboratory investigations. O.L. and F.L. reviewed the Centre national de référence des mycoses invasives et antifongiques (CNRMA) materials. D.G.H. is responsible for mycological laboratory investigations in the CNRMA and performed identification of strains and extended antimicrobial susceptibility. E.H. managed the compassionate use in F2G laboratory. E.F., O.B., and F.L. wrote the manuscript. All co-authors reviewed the manuscript.

About the Author

Dr. Faure is an associate professor at Lille University and infectious disease specialist at Lille University Hospital. His primary interests include infection in immunocompromised hosts and host–pathogen interactions.

References

- Miossec C, Morio F, Lepoivre T, Le Pape P, Garcia-Hermoso D, Gay-Andrieu F, et al. Fatal invasive infection with fungemia due to *Microascus cirrosus* after heart and lung transplantation in a patient with cystic fibrosis. *J Clin Microbiol*. 2011;49:2743–7. <https://doi.org/10.1128/JCM.00127-11>
- Liu Q, Kong L, Hua L, Xu S. Pulmonary *Microascus cirrosus* infection in an immunocompetent patient with bronchiectasis: a case report. *Respir Med Case Rep*. 2021;34:101484. <https://doi.org/10.1016/j.rmcr.2021.101484>
- Georgacopoulos O, Nunnally NS, Ransom EM, Law D, Birch M, Lockhart SR, et al. In vitro activity of novel antifungal olorofim against filamentous fungi and comparison to eight other antifungal agents. *J Fungi (Basel)*. 2021;7:378. <https://doi.org/10.3390/jof7050378>
- Wiederhold NP. Review of the novel investigational antifungal olorofim. *J Fungi (Basel)*. 2020;6:122. <https://doi.org/10.3390/jof6030122>
- Wiederhold NP, Patterson HP, Sanders CJ, Cañete-Gibas C. Dihydroorotate dehydrogenase inhibitor olorofim has potent in vitro activity against *Microascus/Scopulariopsis*, *Rasamsonia*, *Penicillium* and *Talaromyces* species. *Mycoses*. 2023;66:242–8. <https://doi.org/10.1111/myc.13548>
- Schoeppler KE, Zamora MR, Northcutt NM, Barber GR, O'Malley-Schroeder G, Lyu DM. Invasive *Microascus trigonosporus* species complex pulmonary infection in a lung transplant recipient. *Case Rep Transplant*. 2015;2015:745638. <https://doi.org/10.1155/2015/745638>
- Woudenberg JHC, Meijer M, Houbraken J, Samson RA. *Scopulariopsis* and *scopulariopsis*-like species from indoor environments. *Stud Mycol*. 2017;88:1–35. <https://doi.org/10.1016/j.simyco.2017.03.001>
- Aguilar C, Pujol I, Guarro J. In vitro antifungal susceptibilities of *Scopulariopsis* isolates. *Antimicrob Agents Chemother*. 1999;43:1520–2. <https://doi.org/10.1128/AAC.43.6.1520>
- Cuenca-Estrella M, Gomez-Lopez A, Buitrago MJ, Mellado E, Garcia-Effron G, Rodriguez-Tudela JL. In vitro activities of 10 combinations of antifungal agents against the multiresistant pathogen *Scopulariopsis brevicaulis*. *Antimicrob Agents Chemother*. 2006;50:2248–50. <https://doi.org/10.1128/AAC.00162-06>
- Skóra M, Bulanda M, Jagielski T. *In vitro* activities of a wide panel of antifungal drugs against various *Scopulariopsis* and *Microascus* species. *Antimicrob Agents Chemother*. 2015;59:5827–9. <https://doi.org/10.1128/AAC.00978-15>

Address for correspondence: Emmanuel Faure, CHRU de Lille—Service Universitaire de Maladies infectieuses, 1 rue Michel Polonovski Lille Nord 59037, France; email: emmanuel.faure@univ-lille.fr

Tuberculosis Variant with Rifampin Resistance Undetectable by Xpert MTB/RIF, Botswana

Chawangwa Modongo, Ivan Barilar, Qiao Wang, Tuduetso Molefi, Topo Makhondo, Stefan Niemann, Sanghyuk S. Shin

Author affiliations: Victus Global Botswana Organisation, Gaborone, Botswana (C. Modongo); Forschungszentrum, Borstel, Germany (I. Barilar, S. Niemann); University of California, Irvine, California, USA (Q. Wang, S.S. Shin); University of California, Los Angeles, California, USA (Q. Wang); Botswana Ministry of Health and Wellness, Gaborone (T. Molefi, T. Makhondo); German Center for Infection Research, Partner Site Hamburg-Lübeck-Borstel-Riems, Borstel, Germany (S. Niemann)

GeneXpert MTB/RIF, a tool widely used for diagnosing tuberculosis, has limitations for detecting rifampin resistance in certain variants. We report transmission of a pre-extensively drug-resistant variant in Botswana that went undetected by GeneXpert. The public health impact of misdiagnosis emphasizes the need for comprehensive molecular testing to identify resistance and guide treatment.

DOI: <https://doi.org/10.3201/eid2911.230987>

The GeneXpert (Xpert) MTB/RIF assay (Cepheid, <https://www.cepheid.com>) has enabled rapid molecular diagnosis of tuberculosis (TB) and identification of resistance to rifampin, a critical first-line TB drug (1). Operating with minimal infrastructure in a cartridge-based system, the assay is the primary TB diagnostic method in many countries (2). Xpert

EID cannot ensure accessibility for supplementary materials supplied by authors. Readers who have difficulty accessing supplementary content should contact the authors for assistance.

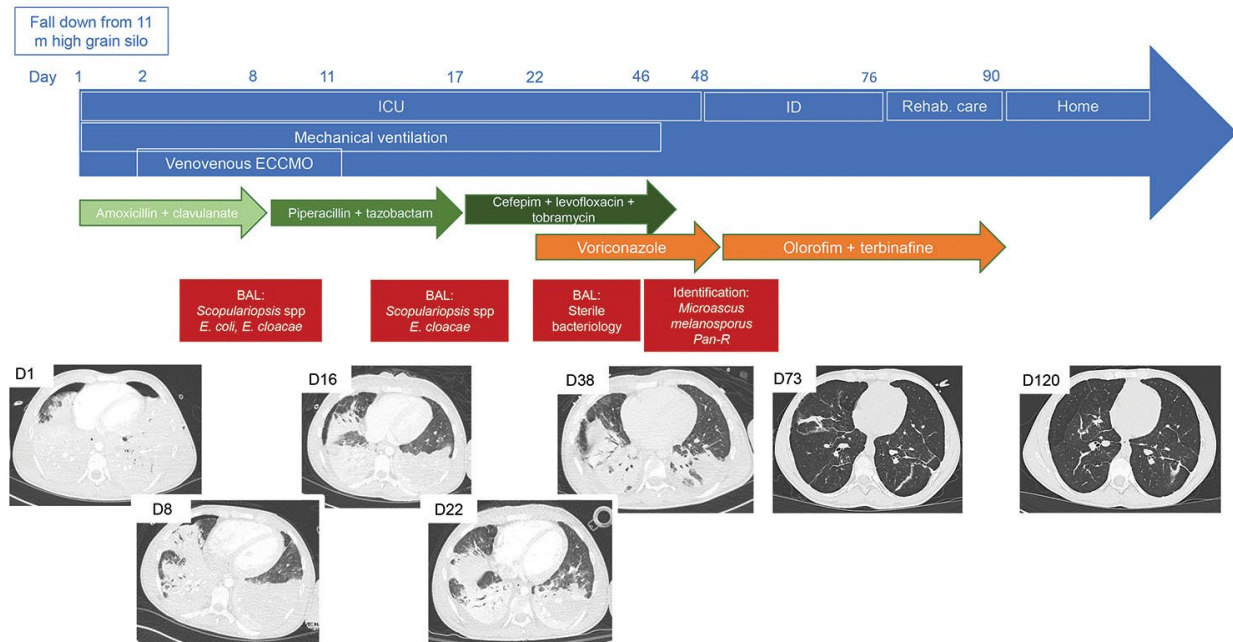
Refractory *Microascus* Bronchopulmonary Infection Treated with Olorofim, France

Appendix

Appendix Table. Antifungal susceptibility testing of *Microascus* spp. strains from 3 cases of refractory microascus bronchopulmonary infection, France*

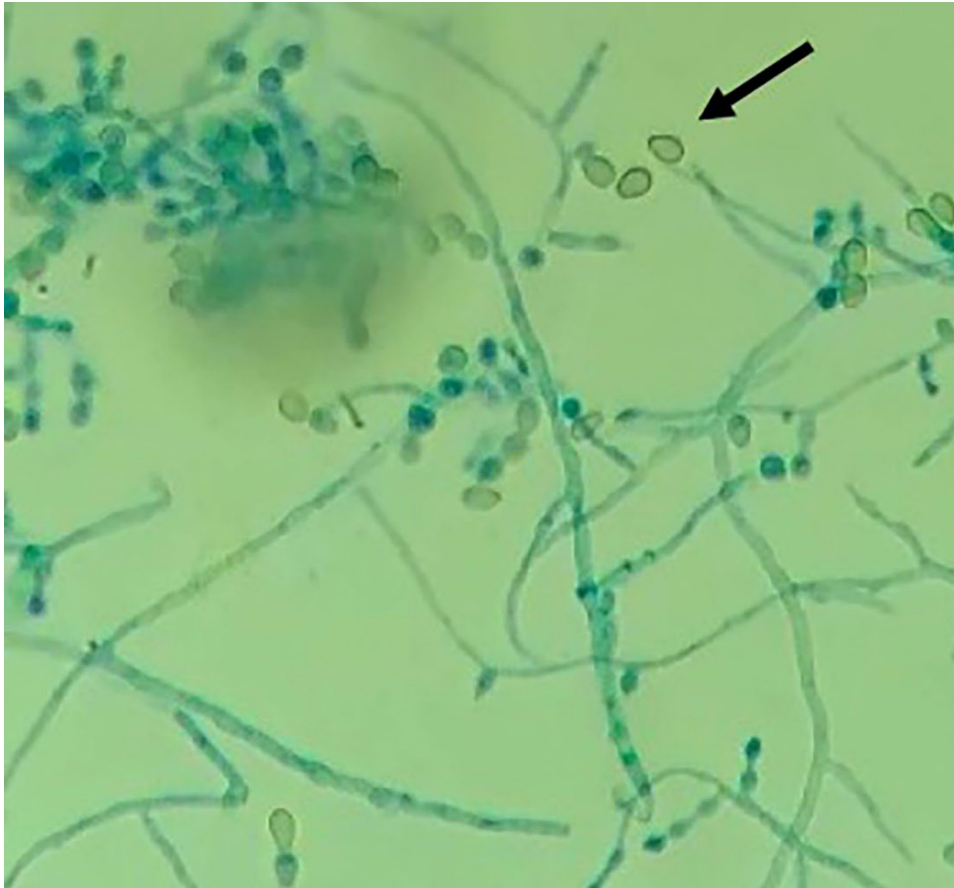Case	Strain	AmB	VCZ	PSZ	ITZ	ISZ	TBF	CAS	MIC	OLO
1	<i>M. melanosporus</i>	8	8	8	16	4	0,25	4	4	0.25
2	<i>M. cirrosus</i>	8	8	16	16	2	2	8	8	0.06
3	<i>M. cirrosus</i>	8	2	2	16	2	2	8	8	0.03

*AmB, amphotericine B; CAS, caspofungin; ISZ, isavuconazole; ITZ, itraconazole; MIC, micafungin; OLO, olorofim; PSZ, posaconazole; TBF, terbinafin; VCZ, voriconazole.

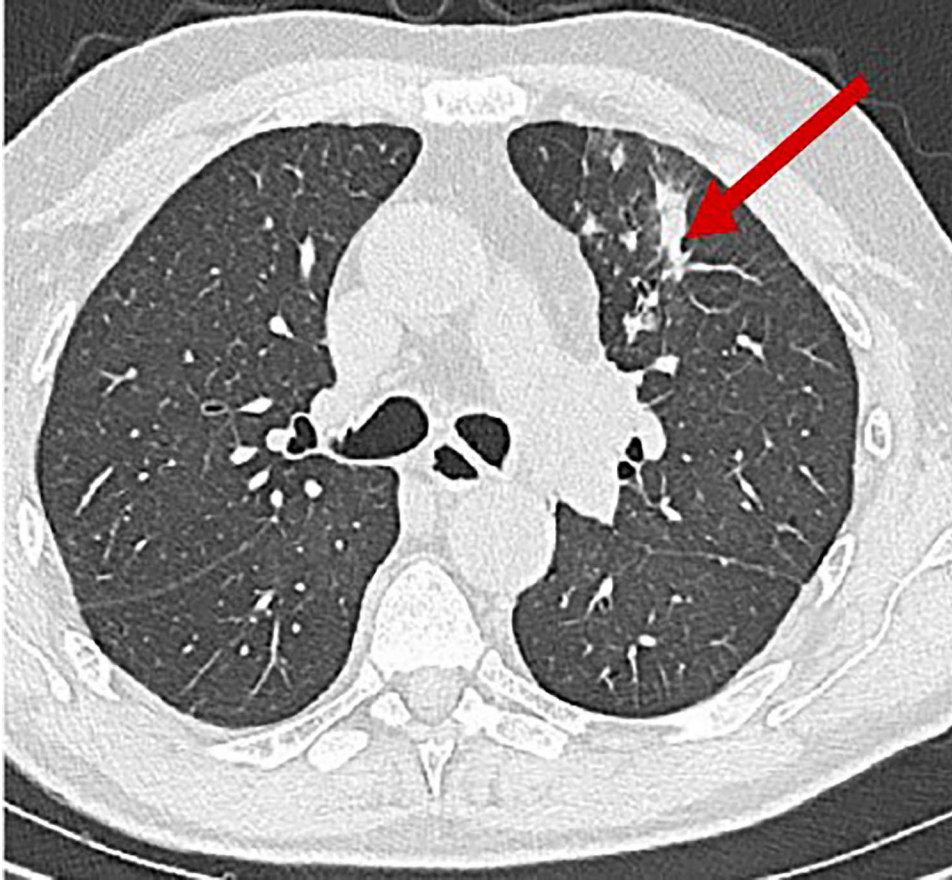


Appendix Figure 1. A) Summary of a case of refractory microascus bronchopulmonary infection in a patient 17 years of age. Day 1 (D1) is the admission in ICU just after the patient fell from a height of 11 m. Green arrows represent BAL the successive antimicrobial therapies for bacterial respiratory infection. Orange arrows are the different antifungal therapies for fungal respiratory infection. Red arrows are the results of

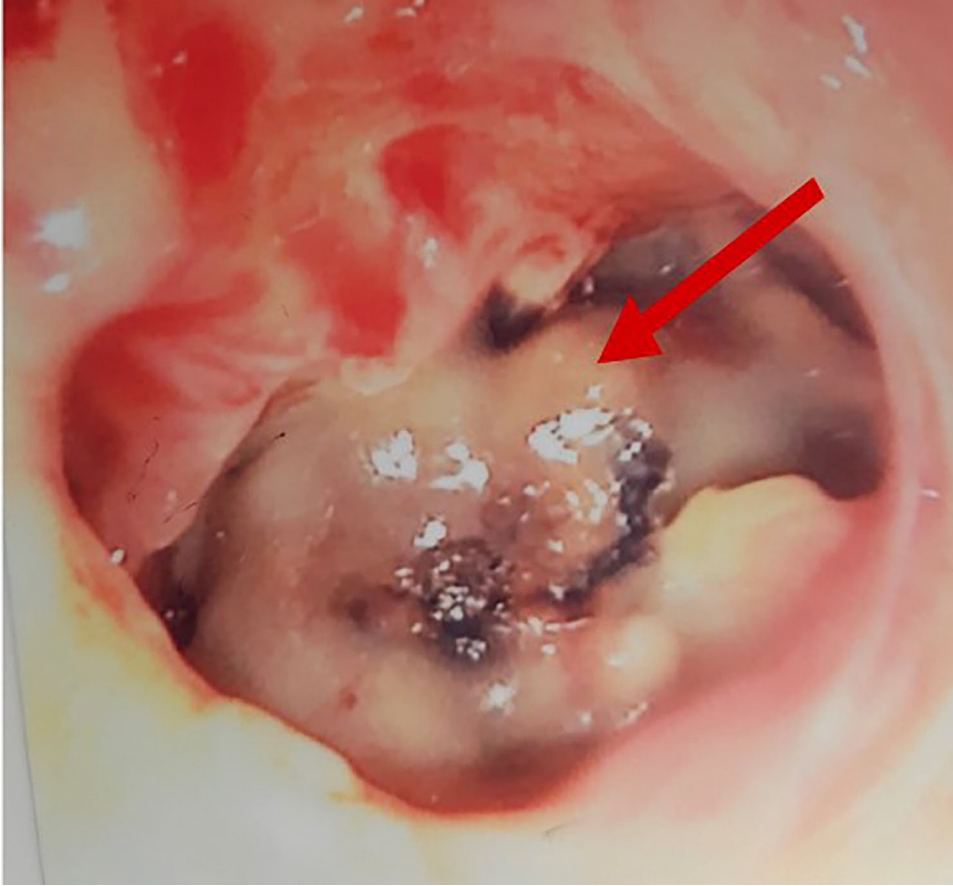
bronchoalveolar lavage fluid cultures. B) Chest computed tomography scans performed during follow-up or at worsening of clinical status. ICU, intensive care unit; ECCMO, extracorporeal continuous membrane oxygenation; ID, infectious disease department; rehab care: rehabilitation care unit; home: day when patient was discharged to his home.



Appendix Figure 2. Microscopy examination (original magnification $\times 40$) of strain of *Microascus melanosporus* after lactophenol cotton-blue stain showing vegetative hyphae, annellides, and truncate conidia.



Appendix Figure 3. Thoracic computed tomography scan of patient with refractory microascus bronchopulmonary infection. Arrow indicates new-onset alveolar condensation in left upper lobe.



Appendix Figure 4. Macroscopic observation of endobronchial *Microascus cirrosus* lesion in case-patient 3 before olorofim treatment. Arrow indicates the lesion.