

References

1. Benzarti E, Linden A, Desmecht D, Garigliany M. Mosquito-borne epornitic flaviviruses: an update and review. *J Gen Virol*. 2019;100:119–32. <https://doi.org/10.1099/jgv.0.001203>
2. Agüero M, Fernández-Pinero J, Buitrago D, Sánchez A, Elizalde M, San Miguel E, et al. Bagaza virus in partridges and pheasants, Spain, 2010. *Emerg Infect Dis*. 2011;17:1498–501. <https://doi.org/10.3201/eid1708.110077>
3. Steyn J, Botha EM, Lourens C, Coetzer JAW, Venter M. Bagaza virus in Himalayan monal pheasants, South Africa, 2016–2017. *Emerg Infect Dis*. 2019;25:2299–302. <https://doi.org/10.3201/eid2512.190756>
4. Gamino V, Gutiérrez-Guzmán AV, Fernández-de-Mera IG, Ortíz JA, Durán-Martín M, de la Fuente J, et al. Natural Bagaza virus infection in game birds in southern Spain. *Vet Res (Faisalabad)*. 2012;43:65. <https://doi.org/10.1186/1297-9716-43-65>
5. Llorente F, Pérez-Ramírez E, Fernández-Pinero J, Elizalde M, Figuerola J, Soriguer RC, et al. Bagaza virus is pathogenic and transmitted by direct contact in experimentally infected partridges, but is not infectious in house sparrows and adult mice. *Vet Res (Faisalabad)*. 2015;46:93. <https://doi.org/10.1186/s13567-015-0233-9>
6. Cano-Gómez C, Llorente F, Pérez-Ramírez E, Soriguer RC, Sarasa M, Jiménez-Clavero MÁ. Experimental infection of grey partridges with Bagaza virus: pathogenicity evaluation and potential role as a competent host. *Vet Res (Faisalabad)*. 2018;49:44. <https://doi.org/10.1186/s13567-018-0536-8>
7. García-Bocanegra I, Zorrilla I, Rodríguez E, Rayas E, Camacho L, Redondo I, et al. Monitoring of the Bagaza virus epidemic in wild bird species in Spain, 2010. *Transbound Emerg Dis*. 2013;60:120–6. <https://doi.org/10.1111/j.1865-1682.2012.01324.x>
8. Elizalde M, Cano-Gómez C, Llorente F, Pérez-Ramírez E, Casades-Martí L, Aguilera-Sepúlveda P, et al. A duplex quantitative real-time reverse transcription-PCR for simultaneous detection and differentiation of flaviviruses of the Japanese encephalitis and Ntaya serocomplexes in birds. *Front Vet Sci*. 2020;7:203. <https://doi.org/10.3389/fvets.2020.00203>
9. Buitrago D, Rocha A, Tena-Tomás C, Vigo M, Agüero M, Jiménez-Clavero MA. Real-time fluorogenic reverse transcription polymerase chain reaction assay for the specific detection of Bagaza virus. *J Vet Diagn Invest*. 2012;24:959–63. <https://doi.org/10.1177/1040638712452723>
10. Sánchez-Seco MP, Rosario D, Domingo C, Hernández L, Valdés K, Guzmán MG, et al. Generic RT-nested-PCR for detection of flaviviruses using degenerated primers and internal control followed by sequencing for specific identification. *J Virol Methods*. 2005;126:101–9. <https://doi.org/10.1016/j.jviromet.2005.01.025>

Address for correspondence: João Queirós, CIBIO, Centro de Investigação em Biodiversidade e Recursos Genéticos, INBIO Laboratório Associado, BIOPOLIS Program in Genomics, Biodiversity and Land Planning, Campus de Vairão, Universidade do Porto, 4485-661 Vairão, Portugal; email: joao.queiros@cibio.up.pt

Hodgkin Lymphoma after Disseminated *Mycobacterium genavense* Infection, Germany

Janina Trauth, Thomas Discher, Moritz Fritzenwanker, Can Imirzalioglu, Tobias Arnold, Dagmar Steiner, Elvira Richter, Laura Crisponi, Bodo Grimbacher, Susanne Herold

Author affiliations: Justus Liebig University, Giessen, Germany (J. Trauth, T. Discher, M. Fritzenwanker, C. Imirzalioglu, S. Herold); University Hospital Gießen, Gießen (T. Arnold, D. Steiner); MVZ Labor Doctor Limbach and Kollegen, Heidelberg, Germany (E. Richter); Istituto di Ricerca Genetica e Biomedica, Consiglio Nazionale delle Ricerche (CNR), Monserrato, Cagliari, Italy (L. Crisponi); Medical Center—University of Freiburg, Freiburg, Germany (L. Crisponi, B. Grimbacher)

DOI: <http://doi.org/10.3201/eid2807.220425>

Mycobacterium genavense infection, a rare nontuberculous mycobacteria infection, occurs in heavily immunocompromised patients (i.e., those with advanced HIV disease, genetic disorders, or acquired immunologic disorders and those undergoing immunosuppressive therapy). We report a case of disseminated *M. genavense* infection preceding Hodgkin lymphoma in a patient without obvious risk factors for this infection.

Mycobacterium genavense was first described in 1992 in HIV-positive patients with low CD4 counts and disseminated mycobacterial disease (1). Since the 2000s, additional risk factors for this bacterial infection became known (e.g., solid organ transplantation, hematopoietic stem cell transplantation, Epstein-Barr virus-associated lymphoproliferative disorder, neutralizing anti-interferon γ autoantibodies, adenosine deaminase deficiency, nuclear factor κ B1 deficiency) (2,3). Clinical manifestations of *M. genavense* commonly involve blood and lymph nodes but can include the gastrointestinal tract, spleen, liver, and bone marrow; pneumonia, prosthetic joint infection, endobronchial mass, and brain mass have also been described.

A previously healthy 23-year-old woman sought medical treatment at University Hospital Gießen (Gießen, Germany) for progressive cervical lymphadenopathy (Figure, panel A) and fever originating 4 months prior. A professional animal keeper, she had no history of previous infections or autoimmune disease, an unremarkable family history, and no travel outside of Europe; her tattoos showed no signs of irritation. She experienced gender dysphoria and used masculinizing hormone therapy (testosterone). We

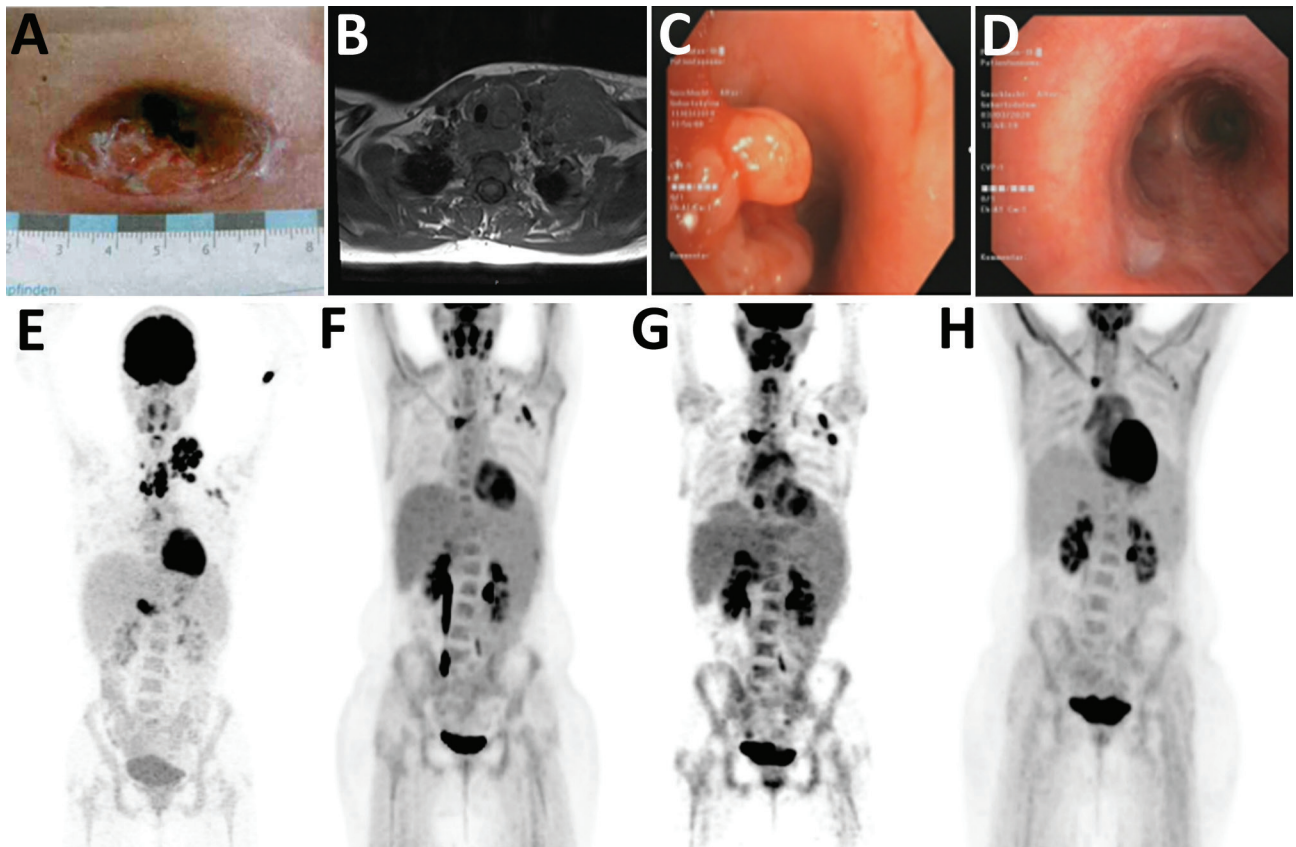


Figure. Clinical manifestations and radiologic findings in the course of disease in a 23-year-old woman with disseminated *M. genavense* infection preceding Hodgkin lymphoma, Germany. A) Cervical wound after initial lymph node extirpation. B) Magnetic resonance imaging at the time of initial evaluation. C) Endobronchial view of tracheo-esophageal fistula before positioning of a stent. D) Endobronchial view of the prior tracheo-esophageal fistula after treatment. Whitish scar tissue is seen at the bottom left. E) ^{18}F -FDG-PET scan at initial evaluation (maximum intensity projection). Cervical lymph node mass is seen, with no pathologic uptake in the abdomen. F) ^{18}F -FDG-PET scan after 6 months of antibiotic treatment showing reduced uptake. G) ^{18}F -FDG-PET scan shortly before Hodgkin lymphoma was diagnosed showing new hepatosplenomegaly and lymphadenopathy. H) ^{18}F -FDG-PET scan after antibiotic and chemotherapy without pathologic enhancement

excluded common causes of cervical lymphadenopathy (e.g., HIV, tuberculosis, bacterial abscess, Epstein-Barr virus, lymphoma, toxoplasmosis, bartonellosis, and syphilis), but the extensive lymphadenopathy pointed to a severe disease (Figure, panel B, E). Multiple conglomerate, necrotizing mediastinal lymph nodes resulted in a tracheo-esophageal fistula (Figure, panel C), which required esophageal stenting.

Cervical lymph nodes showed a necrotizing, giant cell-containing inflammatory reaction. We detected acid-fast bacteria on microscopic examination and subsequently identified it as *M. genavense* by using broad-range 16S-rDNA PCR and Sanger sequencing of the resulting amplicon (Appendix, <https://wwwnc.cdc.gov/EID/article/28/7/22-0425-App1.pdf>). In blood and bone marrow, we detected no mycobacteria. From culture on solid medium and mycobacteria growth indicator tube, we were unable to recover outgrowth. *M. genavense* cannot be cultivated in rou-

tine liquid and solid media (Löwenstein-Jensen and Stonebrink) but requires special supplementation for recovery on culture (Middlebrook 7H11 agar [ThermoFisher, <https://www.thermofisher.com>] supplemented with mycobactin J) and an incubation period >100 days. Standardized susceptibility testing is not available (4).

For this nontuberculous mycobacteria (NTM) disease, diagnostic criteria are ill defined and no treatment guidelines are established. Reported case-patients are treated with a 2- to 4-drug regimen, including mostly macrolides, rifampin, ethambutol, and amikacin or fluoroquinolones. The regimen for this patient consisted of clarithromycin, rifabutin, ethambutol, and temporary add-on doses of levofloxacin, amikacin, clofazimine, or bedaquiline. During the ensuing months, the wounds and tracheo-esophageal fistula slowly healed (Figure, panel D), and imaging showed decreased uptake (Figure, panel F).

As a professional pet keeper, the patient had close contact with domestic animals, including birds. Zoonotic transmission of *M. genavense* has not been well described (5), but it does pose a potential risk for susceptible hosts. Because a predisposing risk factor for the patient's NTM disease had not been identified, we ruled out several conditions: acquired immunodeficiency, idiopathic CD4 lymphocytopenia, Mendelian susceptibility to mycobacterial disease, and neutralizing anti-interferon γ autoantibodies or a defect in the (proximal) interferon γ receptor signaling pathway (data not shown). A targeted gene panel with a focused analysis on 810 genes associated with immune and blood disorders did not identify a genetic variant that could alone explain the phenotype; however, we detected several rare variants (Appendix).

After 11 months of antibiotic therapy, an ^{18}F -FDG-PET scan revealed new lymphadenopathy and splenomegaly (Figure, panel G). CD4-to-CD8 ratio dropped from 1.7 to 1.0, and we found new low-level EBV viremia (350 copies/mL). On the basis of new tissue samples from mediastinal lymph nodes, we diagnosed classical Hodgkin lymphoma (HL [mixed type]) stage IV. Mycobacterial PCR was negative in all these samples and, retrospectively, all previous samples were tumor-free. Six cycles of chemotherapy (brentuximab combined with doxorubicin, vinblastine, dacarbazine) were followed by 4 doses of nivolumab because of histologically confirmed mixed response. One year after treatment completion and cessation of antimycobacterial therapy, liquid biopsy and an ^{18}F -FDG-PET scan showed complete remission and no signs of NTM infection (Figure, panel H).

In other reports of *M. genavense* infections related to lymphomas, patients acquired the infection during immunosuppressive therapy; however, in this patient, infection preceded HL. Genetic and environmental factors are relevant in the pathogenesis of HL (6) and in pathogenic pathways triggered by virus infections (e.g., HIV and Epstein-Barr virus) (7); bacterial antigen triggering has been implicated recently in early developmental stages of the disease (8). Other reports have discussed an increased risk for HL after tuberculosis infection (9) and HL associated with concomitant tuberculosis, leprosy, and *Mycobacterium avium* complex disease (10).

M. genavense remains a diagnostic challenge because standard media and incubation times do not yield bacterial growth, which can result in missed diagnoses. Research is needed to gain a clear understanding of the interplay of NTM and HL, specifically in regard to how mycobacterial antigens trigger pathogenic pathways during HL development

and the role of HL in causing local immune escape mechanisms and immunologic imbalance resulting in susceptibility to infections.

In conclusion, we report a patient with disseminated *M. genavense* infection preceding HL who recovered after antimycobacterial therapy and first- and second-line chemotherapy. A zoonotic source of *M. genavense* infection is likely. Furthermore, because sex hormones affect immunity and testosterone is a susceptibility factor for mycobacterial disease, masculinizing hormone therapy could have contributed to susceptibility.

About the Author

Dr. Trauth is attending physician at University Hospital Gießen, Germany. Her primary interests include pulmonary infections and antibiotic stewardship.

References

- Böttger EC, Teske A, Kirschner P, Bost S, Chang HR, Beer V, et al. Disseminated "*Mycobacterium genavense*" infection in patients with AIDS. *Lancet*. 1992;340:76–80. [https://doi.org/10.1016/0140-6736\(92\)90397-L](https://doi.org/10.1016/0140-6736(92)90397-L)
- Bustamante J, Boisson-Dupuis S, Abel L, Casanova J-L. Mendelian susceptibility to mycobacterial disease: genetic, immunological, and clinical features of inborn errors of IFN- γ immunity. *Semin Immunol*. 2014;26:454–70. <https://doi.org/10.1016/j.smim.2014.09.008>
- Mahmood M, Ajmal S, Abu Saleh OM, Bryson A, Marcelin JR, Wilson JW. *Mycobacterium genavense* infections in non-HIV immunocompromised hosts: a systematic review. *Infect Dis (Lond)*. 2018;50:329–39. <https://doi.org/10.1080/23744235.2017.1404630>
- Griffith DE, Aksamit T, Brown-Elliott BA, Catanzaro A, Daley C, Gordin F, et al.; ATS Mycobacterial Diseases Subcommittee; American Thoracic Society; Infectious Disease Society of America. An official ATS/IDSA statement: diagnosis, treatment, and prevention of nontuberculous mycobacterial diseases. *Am J Respir Crit Care Med*. 2007;175:367–416. <https://doi.org/10.1164/rccm.200604-571ST>
- Schmitz A, Korb R, Thiel S, Wörle B, Gohl C, Rinder M. High prevalence of *Mycobacterium genavense* within flocks of pet birds. *Vet Microbiol*. 2018;218:40–4. <https://doi.org/10.1016/j.vetmic.2018.03.026>
- Cartwright RA, Watkins G. Epidemiology of Hodgkin's disease: a review. *Hematol Oncol*. 2004;22:11–26. <https://doi.org/10.1002/hon.723>
- Carbone A, Gloghini A, Caruso A, De Paoli P, Dolcetti R. The impact of EBV and HIV infection on the microenvironmental niche underlying Hodgkin lymphoma pathogenesis. *Int J Cancer*. 2017;140:1233–45. <https://doi.org/10.1002/ijc.30473>
- Weniger MA, Küppers R. Molecular biology of Hodgkin lymphoma. *Leukemia*. 2021;35:968–81. <https://doi.org/10.1038/s41375-021-01204-6>
- Li G, Chen G-L, Zhou Y, Yao G-Q, Yang S, Ji D-M. Increased risk of lymphoma in men or the elderly infected with tuberculosis. *Mediterr J Hematol Infect Dis*. 2021;13:e2021053. <https://doi.org/10.4084/MJHID.2021.053>

10. Varkey MR, Ali J, Lapinel NC. The chicken and the egg dilemma: a case of disseminated MAC with Hodgkin's lymphoma. *Respir Med Case Rep.* 2020;31:101253. <https://doi.org/10.1016/j.rmcr.2020.101253>

Address for correspondence: Janina Trauth, University Hospital Gießen and Marburg GmbH, Section of Infectious Diseases, Klinikstr 33, 35392 Gießen, Germany; email: janina.trauth@innere.med.uni-giessen.de

Natural Reassortment of Eurasian Avian-Like Swine H1N1 and Avian H9N2 Influenza Viruses in Pigs, China

Wanying Sun,¹ Samuel S.M. Cheng,¹ Kristy N.T. Lam, Tsz C. Kwan, Ricky W.K. Wong, Leo H.K. Lau, Gigi Y.Z. Liu, Leo L.H. Luk, John K.C. Li, Haogao Gu, Malik Peiris, Leo L.M. Poon

Author affiliations: School of Public Health, The University of Hong Kong, Hong Kong, China (W. Sun, S.S.M. Cheng, K.N.T. Lam, T.C. Kwan, R.W.K. Wong, L.H.K. Lau, G.Y.Z. Liu, L.L.H. Luk, J.K.C. Li, H. Gu, M. Peiris, L.L.M. Poon); Centre for Immunology and Infection, Hong Kong (M. Peiris, L.L.M. Poon); HKU-Pasteur Research Pole, The University of Hong Kong, Hong Kong (M. Peiris, L.L.M. Poon)

DOI: <http://doi.org/10.3201/eid2807.220642>

Several zoonotic influenza A viruses detected in humans contain genes derived from avian H9N2 subtypes. We uncovered a Eurasian avian-like H1N1 swine influenza virus with polymerase basic 1 and matrix gene segments derived from the H9N2 subtype, suggesting that H9N2 viruses are infecting pigs and reassorting with swine influenza viruses in China.

Swine are regarded as a mixing vessel for influenza A viruses (IAVs) (1). Avian, swine, and human IAVs can co-infect pigs and generate novel reassortants of zoonotic or pandemic potential.

The emergence of pandemic H1N1 IAV (pH1N1), containing viral segments from avian, swine, and human viruses, highlighted the key role of pigs in contributing to IAV reassortment and evolution (2). Research in China also showed evidence of avian H5, H7, H9, and H10 influenza infections in pigs (3). Avian IAVs linked to human infection in this region contained internal genes derived from avian H9N2 viruses, indicating that the internal genes of the H9N2 virus might aid zoonotic transmission (4). We report detection of a swine IAV with polymerase basic (PB) 1 and matrix (M) gene segments of avian H9N2 origin.

In April 2021, we resumed monthly influenza surveillance program of imported pigs in a local slaughterhouse, which had been interrupted by COVID-19 outbreaks (5). We collected individual nasal swab samples (≈75 samples per visit), which we kept chilled in virus transport medium until they reached the laboratory. We then subjected swab samples to IAV isolation by using MDCK cells, as previously described (2). We identified cultures with cytopathic effect and tested them using a standard hemagglutination assay with turkey red blood cells. We tested hemagglutination-positive cultures with a universal influenza reverse transcription PCR assay specific for M segments (6). We studied samples that were positive for this reaction by using next-generation sequencing to deduce the full virus genomes (6).

During April 2021–February 2022, we collected a total of 829 porcine nasal swab samples (Table). We isolated 8 IAVs: 7 from August 2021 and 1 from September 2021. Virus sequences deduced from this study are available from GISAID (isolate nos. EPI_ISL_12471293–300). We compared those sequences with reference sequences (Appendix Table, <https://wwwnc.cdc.gov/EID/article/28/7/22-0642-App1.pdf>). IAVs detected in August 2021 were H3N2 viruses. The hemagglutinin (HA) and neuraminidase (NA) segments of those viruses were associated with human-like H3N2 swine influenza A virus; however, their internal gene segments all were derived from the pH1N1 lineage (Figure; Appendix Figures 1–6). These viruses were genetically not identical but highly similar. The influenza-positive pigs came from farms located in 2 provinces across southern China. Because this slaughterhouse followed a daily clearance policy requiring that all imported live pigs be slaughtered within 24 hours of admittance, our results suggest influenza transmission between pigs in the pre-slaughter transport chain outside Hong Kong. This

¹These authors contributed equally to this article.

Hodgkin Lymphoma after Disseminated *Mycobacterium genavense* Infection, Germany

Appendix

Experimental procedure and description of the applied methodology

Experimental procedure

The DNA sample was analyzed using Next Generation DNA Sequencing technology. First, it was subjected to a standard quality control procedure and subsequently enriched and processed into a DNA library using the custom CeGaT_BID2 capture design, focused on the analysis of 810 genes associated with Immune and Blood Disorders. Second, the resulting targeted gene panel (TGP) library was checked and sequenced in a NovaSeq 6000 instrument.

Bioinformatics analysis

Raw data (FASTQ files) were processed using a custom bioinformatic pipeline that includes quality control, read trimming, alignment, variant calling with the FreeBayes, SamTools and GATK algorithms, and variant annotation using the VEP software from Ensembl. Resulting datasets were imported into our in-house SQL database, which were used to analyze and filter out common variants present in the general population or variants with a low predicted impact on protein function. Before filtering, a total of 5114 variants against the reference human genome (Dec. 2013, GRCh38/hg38) were identified in the sample.

Results interpretation

Variant prioritization and classification was done using in-house-developed algorithms. For this study, we mainly considered rare variants (allele frequency below 1% in control populations). We did not identify one genetic variant that could alone explain the phenotype for the patient; however, we detected several rare variants that were of interest:

- 1) A heterozygous missense variant in *WAS* (c.995T>C, p.Val332Ala), which in the literature has been associated with X-linked thrombocytopenia in 2 cases, 1 being a

- female carrier with a fully inactivated normal chromosome (1,2). Typically, patients with X-linked thrombocytopenia do not have significant immunodeficiency, but they do have an increased risk of malignancy (3).
- 2) A heterozygous missense variant in *IL17RA* (c.2245G>A, p.Glu749Lys); biallelic mutations in this gene can cause Immunodeficiency 51, an autosomal recessive disease characterized by chronic mucocutaneous candidiasis.
 - 3) A novel variant of uncertain significance in *MEFV* (c.835G>A, p.Ala279Thr).
 - 4) A probably benign variant in *TAC1* (c.659T>C, p.Val220Ala).

Description of the applied methodology

Initial mycobacteria real-time PCR: DNA extraction from lymph-node-tissue was performed by an automated extraction system using a tissue protocol (eMAG, bioMérieux, <https://www.biomerieux.com>). The resulting DNA-extract was submitted to real-time PCR using the commercially available Anyplex MTB/NTMe Real-time Assay (Seegene, <https://www.seegene.com>), which allows detection of either *Mycobacterium tuberculosis* or broad-range nontuberculous mycobacteria. This assay, however, yielded only negative results, which might be due to an insufficient DNA-extraction protocol or lack of coverage for *Mycobacterium genavense* by the applied nontuberculous mycobacteria primers in the assay.

Broad-range 16S-rDNA PCR and amplicon sequencing: DNA extraction from lymph-node-tissue samples was performed using the PureLink Pro 96 Genomic DNA Purification Kit (Invitrogen, Fisher Scientific, <https://www.fishersci.com/>). 16S-rDNA PCR from extract was performed as previously described (4,5) using primers 933F (5' GCA CAA GCG GTG GAG CAT GTG G 3') and 1407R (5' GAT GGG CGG TCT GTA CAA G 3'). The amplification products were analyzed for an expected 474bp amplicon by gel electrophoresis with a horizontal 1.5% agarose gel for 1 hour at 150 V at room temperature in TBE running buffer and then purified using the MSB[®] Spin PCRapace Kit (Invitex, <https://invitek-molecular.com>). Purified DNA underwent Sanger-sequencing at an external certified and quality-controlled service-provider (Eurofins, <https://eurofins.com>).

PCR/sequencing positive control: *Escherichia coli* ATCC 25922. Reads were preliminarily analyzed at <http://www.sepsitest-blast.de/de/index.html>, both forward and reverse

reads yielding *M. genavense* (identity 99.8%; alignment length 417 (100.0%); E-value = 0.0; Accession = X60070 and identity 99.8%; alignment length 420 (98.6%); E-value = 0.0; Accession = X60070).

To verify, reads were then analyzed with CLC Genomics Workbench (v 12.0), QIAGEN Aarhus A/S, assembled with tracy assemble (v 0.6.1) on Galaxy Europe Server (6,7). The consensus was analyzed with BLASTN at NCBI nucleotide database (8,9), yielding multiple alignments, the best hit being *M. genavense* strain 2289, E value 0.0, identity 99.79% (476/477), gaps 0/477, score 876 bits, sequence ID NR 029223.1. Lower percentage hits were associated with other mycobacterial species.

To further confirm results, original samples were sent to Limbach laboratory (Germany) for independent PCR and sequence analysis. A lymph node biopsy was obtained for mycobacterial culture, and PCR analysis was performed for mycobacterial DNA. The minced tissue was decontaminated using the NALC-NaOH procedure (10) for mycobacterial culture. The resulting sediment was divided—one part was used for smear microscopy and was inoculated into MGIT liquid media and placed onto solid Löwenstein and Stonebrink slants, and the second part was used for molecular analyses by preparing DNA using the Fluorolyse technology (Bruker HAIN, <https://bruker.com>). A specific nested amplification protocol targeting the mycobacterial 16S rRNA gene was performed using primers ‘285’ and ‘264’ for 35 cycles and nested primers ‘B9’ and ‘247’ for an additional 12 cycles (11). The obtained amplicon was sequenced by sanger sequencing using primer ‘B9’, resulting in a sequence of 510 bp, which was compared using the Basic Local Alignment Search Tool (<https://blast.ncbi.nlm.nih.gov/>). *M. genavense* was identified as the causative agent with 100% sequence homology with accession number AF547928 representing the type strain. PCR-negative controls proved negative.

In both laboratories, the smear microscopy of the tissue showed acid-fast bacteria, and liquid and solid cultures remained negative despite prolonged incubation.

The results were confirmed by analyzing a second lymph node biopsy obtained 3.5 months afterward and were also confirmed by the German National Reference Center for Mycobacteria (Borstel, Germany).

References

1. Daza-Cajigal V, Martínez-Pomar N, Garcia-Alonso A, Heine-Suñer D, Torres S, Vega AK, et al. X-linked thrombocytopenia in a female with a complex familial pattern of X-chromosome inactivation. *Blood Cells Mol Dis*. 2013;51:125–9. [PubMed](#) <https://doi.org/10.1016/j.bcnd.2013.04.004>
2. Proust A, Guillet B, Picard C, de Saint Basile G, Pondarré C, Tamary H, et al. Detection of 28 novel mutations in the Wiskott-Aldrich syndrome and X-linked thrombocytopenia based on multiplex PCR. *Blood Cells Mol Dis*. 2007;39:102–6. [PubMed](#) <https://doi.org/10.1016/j.bcnd.2007.02.007>
3. Albert MH, Bittner TC, Nonoyama S, Notarangelo LD, Burns S, Imai K, et al. X-linked thrombocytopenia (XLT) due to WAS mutations: clinical characteristics, long-term outcome, and treatment options. *Blood*. 2010;115:3231–8. [PubMed](#) <https://doi.org/10.1182/blood-2009-09-239087>
4. Domann E, Hong G, Imirzalioglu C, Turschner S, Kühle J, Watzel C, et al. Culture-independent identification of pathogenic bacteria and polymicrobial infections in the genitourinary tract of renal transplant recipients. *J Clin Microbiol*. 2003;41:5500–10. [PubMed](#) <https://doi.org/10.1128/JCM.41.12.5500-5510.2003>
5. Imirzalioglu C, Hain T, Chakraborty T, Domann E. Hidden pathogens uncovered: metagenomic analysis of urinary tract infections. *Andrologia*. 2008;40:66–71. [PubMed](#) <https://doi.org/10.1111/j.1439-0272.2007.00830.x>
- 6) Rausch T, Fritz M H-Y., Untergasser A, Benes V. Tracy: basecalling, alignment, assembly and deconvolution of sanger chromatogram trace files. *BMC Genomics*. 2020;21:230. **PMID 32171249** <https://doi.org/10.1186/s12864-020-6635-8>
7. Afgan E, Baker D, Batut B, van den Beek M, Bouvier D, Čech M, et al. The Galaxy platform for accessible, reproducible and collaborative biomedical analyses: 2018 update. *Nucleic Acids Res*. 2018;46(W1):W537–44. 10.1093/nar/gky379 [PubMed](#) <https://doi.org/10.1093/nar/gky379>
8. Zhang Z, Schwartz S, Wagner L, Miller W. A greedy algorithm for aligning DNA sequences. *J Comput Biol*. 2000;7:203–14. [PubMed](#) <https://doi.org/10.1089/10665270050081478>

9. Morgulis A, Coulouris G, Raytselis Y, Madden TL, Agarwala R, Schäffer AA. Database indexing for production MegaBLAST searches. *Bioinformatics*. 2008;24:1757–64. [PubMed](#)
<https://doi.org/10.1093/bioinformatics/btn322>
10. Martin I, Pfyffer GE, Parrish N. *Mycobacterium*: general characteristics, laboratory detection, and staining procedures [chapter]. In: *Manual of clinical microbiology*. 12th edition. Carroll KC, Pfaller MA, Landry ML, McAdam A, Patel R, Richter SS, et al. (editors). Washington: ASM Press; 2019. p. 562–568.
11. Caulfield AJ, Richter E, Brown-Elliott BA, Wallace Jr RJ, Wengenack NL. *Mycobacterium*: laboratory characteristics of slowly growing mycobacteria other than *Mycobacterium tuberculosis*. In: *Manual of clinical microbiology*. 12th edition. Carroll KC, Pfaller MA, Landry ML, McAdam A, Patel R, Richter SS, et al. (editors). Washington: ASM Press. 2019; 2019. p. 603–604