

Ten-Week Follow-Up of Monkeypox Case-Patient, Sweden, 2022

Aleksandra Pettke, Finn Filén, Katarina Widgren, Andreas Jacks, Hedvig Glans, Sofia Andreasson, Shaman Muradrasoli, Sofia Helgesson, Elenor Hauzenberger, Maria Lind Karlberg, Noura Walai, Annelie Bjerkner, Hadrien Gourlé, Sara Gredmark-Russ, Oskar Karlsson Lindsjö, Klara Sondén,¹ Hilmir Asgeirsson¹

A previously healthy male patient had detectable monkeypox virus DNA in saliva 76 days after laboratory confirmation of infection. A comprehensive characterization of viral kinetics and a detailed follow-up indicated a declining risk for transmission during the weeks after monkeypox symptoms appeared.

Monkeypox is a zoonotic infection caused by monkeypox virus (MPXV), belonging to the *Orthopoxvirus* genus of the Poxviridae family. Monkeypox outbreaks have historically been described mainly in central and west Africa (1). Cases outside Africa are rare and, until 2022, consisted mostly of imported cases, patients' household contacts, and, in some cases, nosocomial infections (2,3). One outbreak in 2003 outside Africa was linked to importing exotic pets (4).

In May 2022, a multinational monkeypox outbreak surfaced; cases were reported from Europe, the Americas, Israel, and Australia. Compared with those in previous outbreaks, these reported patients show a different clinical manifestation of localized rashes and mucosal lesions predominantly in the genital area. Common systemic symptoms included fever and lymphadenopathy. The cases clustered in men who have sex with men (5).

We report a monkeypox case detected in Sweden during the multinational outbreak, focusing on the clinical symptoms, microbial diagnostic findings, and viral kinetics in different sample types over time. Moreover, we report a fast and robust bioinformatics analysis of sequencing data for characterizing cases. We obtained consent from the patient for our study.

The Study

The patient, a previously healthy man with no history of smallpox vaccination, first noticed an inguinal swelling (day 0). The next day, he observed a small skin change on his foreskin, progressing over the next days to a deeper, well-circumscribed lesion with local lymphadenopathy. Fever developed on day 5 and 6, peaking at 39°C. One week after symptom onset, the patient sought care at an outpatient clinic. By then, the fever had subsided. No new lesions appeared. He reported a history of receiving oral sex from several male partners within the 3 weeks before symptom onset. At a follow-up visit on day 11, the lesion had increased in size to 2 cm in diameter. Microbiologic analyses for herpes simplex virus, syphilis, and *Haemophilus ducreyi* returned negative results; because of reports of monkeypox cases in Europe manifesting as unusual genital skin lesions, we initiated analysis for MPXV at the Public Health Agency of Sweden. We performed real-time PCRs for orthopoxvirus DNA and MPXV DNA on the genital lesion swab; results were positive and confirmed by Sanger sequencing of an orthopox-specific PCR product.

The genital lesion slowly healed but with increasing local lymphadenopathy; on day 25, the patient had a ruptured local lymph node with discharge. At a follow-up visit on day 53, the patient was feeling

Author affiliations: Public Health Agency of Sweden, Solna, Sweden (A. Pettke, S. Muradrasoli, S. Helgesson, E. Hauzenberger, M.L. Karlberg, N. Walai, A. Bjerkner, H. Gourlé, O. Karlsson Lindsjö, K. Sondén); Stockholm South General Hospital Skin and Venereology Clinics, Stockholm, Sweden (F. Filén); Stockholm County Council, Stockholm (K. Widgren, A. Jacks); Karolinska Institutet, Stockholm (K. Widgren, H. Glans, S. Gredmark-Russ, K. Sondén, H. Ásgeirsson); Karolinska University Hospital, Stockholm (H. Glans, S. Andreasson, S. Gredmark-Russ, H. Ásgeirsson); Laboratory for Molecular Infection Medicine Sweden, Umeå, Sweden (S. Gredmark-Russ)

DOI: <https://doi.org/10.3201/eid2810.221107>

¹These authors contributed equally to this work.

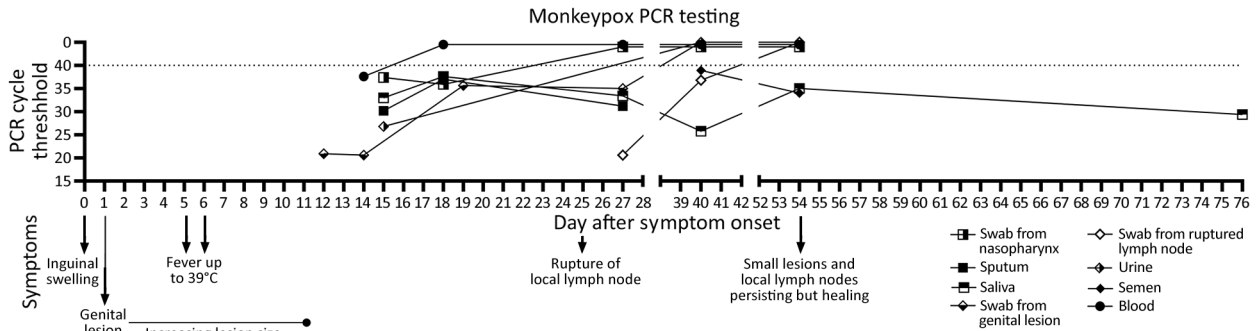


Figure 1. Overview of clinical and laboratory findings in a patient with monkeypox, Sweden, 2022. Timeline depicts clinical symptom evolution and PCR testing results. Dotted line indicates cycle threshold for detection of monkeypox virus by real-time PCR.

well but still had enlarged lymph nodes. The original genital lesion had diminished to 5 mm in diameter and bled slightly when touched. The wound from the ruptured lymph node had healed.

We took repeated samples from the patient during the 10-week follow-up period from the genital lesion, the ruptured local lymph node, urine, semen, blood and the respiratory tract. We detected MPXV DNA in most samples (Figure 1; Appendix Table 1, <https://wwwnc.cdc.gov/EID/article/28/10/22-1107-App1.pdf>). Although tests of all genital samples

were initially positive, all showed a rapid decline in viral DNA content. Of note, MPXV DNA was detected in swabs from the ruptured lymph node 40 days after symptom onset, in semen and saliva after 54 days, and in saliva after 76 days (Figure 1; Appendix Table 1).

We performed electron microscopy on skin lesion material and observed viral particles characteristic for orthopoxviruses (Appendix Figure). The particles were 220–450-nm long and 140–260-nm wide. We extracted DNA from the first genital-

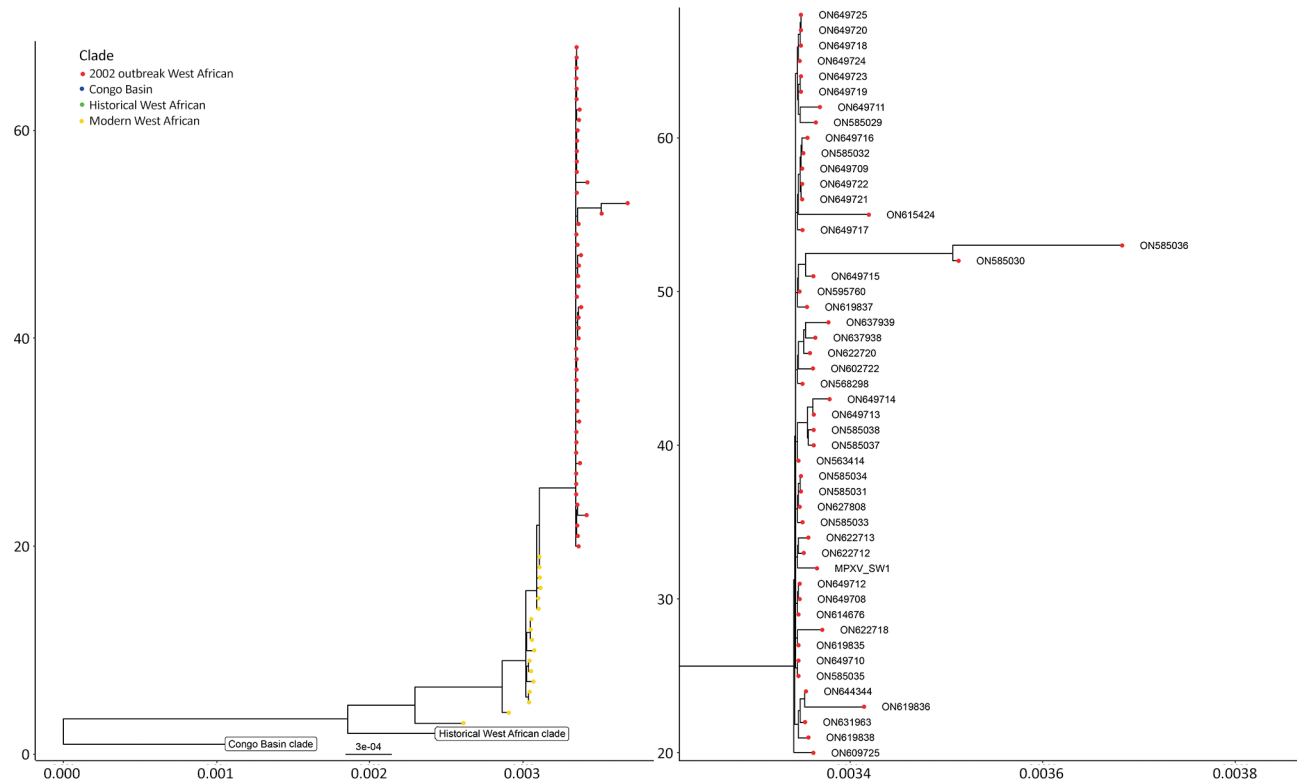


Figure 2. Phylogenetic tree depicting the relationship of the monkeypox virus strain detected in a genital lesion sample from a patient in Sweden to previously published isolates and the strain responsible for the 2022 multinational outbreak. The x-axis represents the branch lengths, interpreted as the number of nucleotide substitutions per site. The y-axis represents the tree cardinality (e.g. the amount of sequences represented in the tree) of each clade.

lesion sample and subjected it to metagenomics sequencing using both short-read and long-read technologies. We reconstructed the viral genome from metagenomics data using a long-read first assembly approach. In brief, reads were cleaned from human sequences using Kraken 2 (<https://github.com/DerrickWood/kraken2>), followed by assembly of the nanopore reads using Flye (<http://github.com/fenderglass/Flye>), resulting in a single contig representing MPXV. The contig was polished using medaka (<https://github.com/nanoporetech/medaka>) for the long reads and then ntEdit (<https://github.com/bcgsc/ntedit>) for the short reads, which produced a nearly complete genome sequence. We compared this genome sequence by whole-genome alignment and tree construction using publicly available sequences (Appendix). The analysis suggested that the case virus belongs to the West Africa clade. Furthermore, the case is closely related with sequences reported from the current outbreak; genome alignment using ViralMSA (<https://github.com/niemasd/ViralMSA>) showed a single-nucleotide polymorphism distance of 4 nt (Figure 2).

Conclusions

As of August 2022, the multinational monkeypox outbreak is still unfolding; new cases are being reported in an increasing number of countries. Many aspects of monkeypox infection in the ongoing outbreak differ from previous endemic and imported monkeypox cases, including clinical manifestations and route of transmission (6,7). The new aspects of the infection have implications for clinical case management and behavioral recommendations for the patient, infection control measures, and public health. More knowledge is urgently needed to control the outbreak at an early stage and prevent virus transmission in previously non-monkeypox-endemic regions.

This report highlights several aspects of monkeypox as an emerging infectious disease. First, the case manifested as a single genital lesion accompanied by enlarged local lymph nodes, leading to lymph node rupture. The appearance of localized genital lesions was consistent with recent reports from other countries in Europe (8) and clearly demonstrated an alternative clinical manifestation of the strain of MPXV associated with the 2022 multinational outbreak, causing localized lesions rather than the classic generalized rash or vesicles spread over the body. Lymph node rupture is an unusual manifestation.

Second, we presented viral kinetics in different sample materials over time and show that, despite

the localized lesion in this patient, viral DNA could also be found in urine, blood, and the respiratory tract. So far, this type of data has been published for few cases (9) within the current multinational outbreak, connected to sexual transmission of MPXV, but this finding is consistent with previous reports from classical monkeypox imported from Africa (2). The persistent detection of MPXV DNA in samples from semen and the respiratory tract in this case could have implications for transmissibility. Prolonged infectivity of bodily fluids such as semen has been described for viral infections like Zika and Ebola (10). However, knowledge gaps include whether a positive PCR result indicates the presence of live virus.

Third, phylogenetic analysis revealed that the virus belongs to the Western Africa clade of monkeypox, which has been associated with lower mortality rates than the Central Africa clade (7,11). Consistent with this classification, the case-patient described had noncritical illness. Furthermore, the sequence showed high degree of similarity to recently published MPXV sequences from Portugal and other countries (12,13).

Within the context of the emerging outbreak of monkeypox, we present comprehensive clinical and microbiologic data with long follow-up times revealing persistent PCR positivity. Previous reports have provided PCR data from single timepoints or short follow-up periods of ≤ 8 days (9,14). Moreover, we present a strategy for adequate sequencing, highlighting a fast but accurate bioinformatics analysis, combining long reads and short reads, that achieves a near-complete genome assembly (Appendix). This analysis will enable other researchers to reliably classify viruses' phylogenetic relationships, which will lead to rapid and accurate epidemiologic case tracing and phylogenetic network analyses at a relatively low cost.

About the Author

Dr. Pettke is a medical doctor working with diagnostics of high-consequence pathogens at the Public Health Agency of Sweden. She has a strong passion and interest for emerging viruses and global health.

References

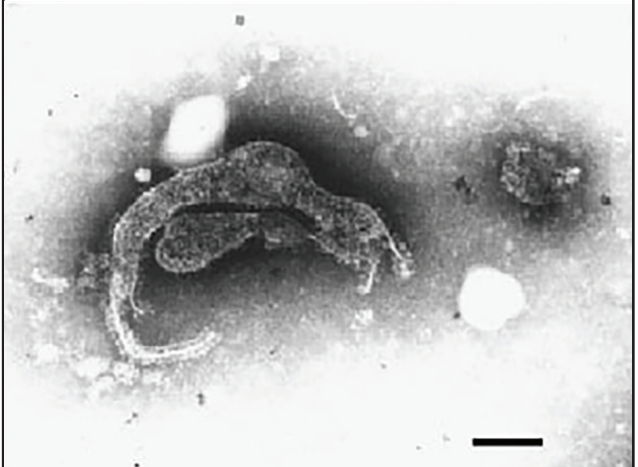
1. World Health Organization. Monkeypox. 2022 [cited 2022 May 30]. <https://www.who.int/news-room/fact-sheets/detail/monkeypox>
2. Adler H, Gould S, Hine P, Snell LB, Wong W, Houlihan CF, et al.; NHS England High Consequence Infectious Diseases (Airborne) Network. Clinical features and management of

- human monkeypox: a retrospective observational study in the UK. *Lancet Infect Dis.* 2022;22:1153–62. [https://doi.org/10.1016/S1473-3099\(22\)00228-6](https://doi.org/10.1016/S1473-3099(22)00228-6)
3. Vaughan A, Aarons E, Astbury J, Brooks T, Chand M, Flegg P, et al. Human-to-human transmission of monkeypox virus, United Kingdom, October 2018. *Emerg Infect Dis.* 2020;26:782–5. <https://doi.org/10.3201/eid2604.191164>
 4. Centers for Disease Control and Prevention. Update: multistate outbreak of monkeypox – Illinois, Indiana, Kansas, Missouri, Ohio, and Wisconsin, 2003. *MMWR Morb Mortal Wkly Rep.* 2003;52:642–6.
 5. Thornhill JP, Barkati S, Walmsley S, Rockstroh J, Antinori A, Harrison LB, et al.; SHARE-net Clinical Group. Monkeypox virus infection in humans across 16 countries – April–June 2022. *N Engl J Med.* 2022;NEJMoa2207323. <https://doi.org/10.1056/NEJMoa2207323>
 6. Brown K, Leggat PA. Human monkeypox: current state of knowledge and implications for the future. *Trop Med Infect Dis.* 2016;1:8. <https://doi.org/10.3390/tropicalmed1010008>
 7. Bunge EM, Hoet B, Chen L, Lienert F, Weidenthaler H, Baer LR, et al. The changing epidemiology of human monkeypox – a potential threat? A systematic review. *PLoS Negl Trop Dis.* 2022;16:e0010141. <https://doi.org/10.1371/journal.pntd.0010141>
 8. European Centre for Disease Prevention and Control. Epidemiological update: monkeypox multi-country outbreak. 2022 [cited 2022 May 30]. <https://www.ecdc.europa.eu/en/news-events/epidemiological-update-monkeypox-multi-country-outbreak>
 9. Antinori A, Mazzotta V, Vita S, Carletti F, Tacconi D, Lapini LE, et al.; INMI Monkeypox Group. Epidemiological, clinical and virological characteristics of four cases of monkeypox support transmission through sexual contact, Italy, May 2022. *Euro Surveill.* 2022;27. <https://doi.org/10.2807/1560-7917.ES.2022.27.22.2200421>
 10. Thorson AE, Deen GF, Bernstein KT, Liu WJ, Yamba F, Habib N, et al.; Sierra Leone Ebola Virus Persistence Study Group. Persistence of Ebola virus in semen among Ebola virus disease survivors in Sierra Leone: a cohort study of frequency, duration, and risk factors. *PLoS Med.* 2021;18:e1003273. <https://doi.org/10.1371/journal.pmed.1003273>
 11. Likos AM, Sammons SA, Olson VA, Frace AM, Li Y, Olsen-Rasmussen M, et al. A tale of two clades: monkeypox viruses. *J Gen Virol.* 2005;86:2661–72. <https://doi.org/10.1099/vir.0.81215-0>
 12. Isidro J, Borges V, Pinto M, Ferreira R, Sobral D, Nunes A, et al. First draft genome sequence of monkeypox virus associated with the suspected multi-country outbreak, May 2022. 2022 [cited 2022 May 30]. <https://virological.org/t/first-draft-genome-sequence-of-monkeypox-virus-associated-with-the-suspected-multi-country-outbreak-may-2022-confirmed-case-in-portugal/799>
 13. GenBank. Monkeypox virus isolate MPXV-BY-IMB25241, complete genome. 2022 [cited 2022 Aug 23]. <https://www.ncbi.nlm.nih.gov/nuccore/ON568298>
 14. Tutu van Furth AM, van der Kuip M, van Els AL, Fievez LC, van Rijckevorsel GG, van den Ouden A, et al. Paediatric monkeypox patient with unknown source of infection, the Netherlands, June 2022. *Euro Surveill.* 2022;27. <https://doi.org/10.2807/1560-7917.ES.2022.27.29.2200552>

Address for correspondence: Klara Sondén, Public Health Agency of Sweden, Department of Microbiology, 171 65 Solna, Sweden; email: klara.sonden@folkhalsomyndigheten.se

EID Podcast

Sentinel Surveillance Shows Novel Hendra Virus in Horses in Australia



Australia hosts over one million horses. Their grazing behavior, large respiratory tidal volume, and highly vascularized upper respiratory epithelium may contribute to their vulnerability for Hendra virus spillover from flying foxes. A novel Hendra virus variant in a horse evaded detection by routine diagnostic testing for Hendra virus because of genomic divergence. This finding indicates a need for increased surveillance in horses and screening of flying foxes for this novel variant.

In this EID podcast, Dr. Edward Annand, an equine veterinarian epidemiologist and a research associate at the University of Sydney School of Veterinary Science in Australia, discusses the detection of a novel Hendra virus variant from a horse in Australia.

Visit our website to listen:
<https://go.usa.gov/xuamj>

**EMERGING
INFECTIOUS DISEASES®**

Ten-Week Follow-Up of Monkeypox Case-Patient, Sweden, 2022

Appendix

Methods

Swab and Sample Collection

Dry swabs were rolled in lesions or other sampling sites and stored at 4-8 degrees Celsius until analysis. Semen and urine were collected in sterile plastic containers without additives. Analyses were performed within 24 hours after sampling.

Total Nucleic Acid Extraction

Total nucleic acid was extracted using QIAamp DNA Blood Mini Kit (QIAGEN, <https://www.qiagen.com>) largely following manufacturer's instructions. A 10-minute heating step at 56 degrees was added for virus inactivation before transfer of the sample on the column. The DNA concentration of the samples was measured on a Qubit Fluorometer following the Qubit dsDNA HS Assay Kit protocol (Invitrogen, <https://www.fishersci.com>).

PCR Testing

Realtime PCR was performed using TaqMan Fast Advanced Master Mix (Thermo Fisher Scientific, <https://www.thermofisher.com>). Primers and probes are listed in Appendix Table 2. Positive and negative controls as well as inhibition and extraction controls are part of the quality control for each PCR. The method has been developed in-house at the Public Health Agency of Sweden (Solna, Sweden).

Metagenomics Sequencing

Ion Torrent sequencing was performed; briefly, Ion Xpress Plus Fragment Library Kit for AB Library Builder System (Thermo Fisher Scientific) was used to generate barcoded Ion fragment DNA libraries from totally 200 ng DNA. The libraries were amplified for 8 cycles according to manufacturer's protocol and then size-selected between 150–330 bp on a Pippin HT

using a 2% agarose gel cassettes (HTC2010, Sage Science, <https://sagescience.com>). The size-selected libraries were purified and quantified by an in-house real-time PCR assay (1). Twenty-five µl of 50 pM of libraries were used for template preparation and Ion 540 chip loading on an Ion Chef system and then sequenced on an Ion GeneStudio S5 Prime system (Thermo Fisher Scientific).

For Nanopore sequencing, 330 ng DNA was treated with RNase A (Sigma Aldrich, <https://www.sigmaaldrich.com>), purified using AMPure XP reagent (Beckman Coulter, <https://www.beckman.com>) and used for library preparation (SQK-RAD004 kit, Oxford Nanopore Technologies <https://nanoporetech.com>). Libraries was loaded on a R9.4.1 flow cell (Oxford Nanopore Technologies) and then sequenced using MinION MK1B and Guppy 5.1.15 in HAC basecalling mode.

Bioinformatics Recovery of Consensus Sequence from Metagenome

Sequencing data was filtered to remove human sequences using Kraken 2 version 2.1.2 using a database built on the RefSeq version of GRCh38.p13 of the human genome (2). Following removal of human sequences, Nanopore reads were assembled using Flye version 2.9 (running with nanopore high-quality settings) (3). The draft assembly was then polished using medaka version 1.6.0 (using medaka consensus with model r941_min_hac_g507) (4). Polished assembly was corrected for platform-specific errors using nteedit version 1.3.5 (using a 40-mer bloom filter) with the read dataset from IonTorrent (5).

Phylogeny

Phylogeny was built using ViralMSA for alignment toward the reference sequence (NC_003310.1), followed by iqtree using the HKY+G model, and 1,000 rapid bootstraps with bnni, reducing the risk of overestimating branch support (6,7). Additionally, cowpox (X94355.2) and horsepox (DQ792504.1) were added as outgroups for rooting the phylogeny.

The resulting consensus-tree was rerooted using gotree with cowpox and horsepox as outgroups (8). The following tree was pruned of the sequence KC257459.1 due to a long branch on the resulting tree.

Monkeypox outbreak genomes come from the sources listed (9–13), enabled by data from GenBank, INSA, and CDC.

References

1. Scaramozzino N, Ferrier-Rembert A, Favier AL, Rothlisberger C, Richard S, Crance JM, et al. Real-time PCR to identify variola virus or other human pathogenic orthopox viruses. *Clin Chem*. 2007;53:606–13. [PubMed https://doi.org/10.1373/clinchem.2006.068635](https://doi.org/10.1373/clinchem.2006.068635)
2. Beser J, Hallström BM, Advani A, Andersson S, Östlund G, Winięcka-Krusnell J, et al. Improving the genotyping resolution of *Cryptosporidium hominis* subtype IbA10G2 using one step PCR-based amplicon sequencing. *Infect Genet Evol*. 2017;55:297–304. [PubMed https://doi.org/10.1016/j.meegid.2017.08.035](https://doi.org/10.1016/j.meegid.2017.08.035)
3. Wood DE, Lu J, Langmead B. Improved metagenomic analysis with Kraken 2. *Genome Biol*. 2019;20:257. [PubMed https://doi.org/10.1186/s13059-019-1891-0](https://doi.org/10.1186/s13059-019-1891-0)
4. Kolmogorov M, Yuan J, Lin Y, Pevzner PA. Assembly of long, error-prone reads using repeat graphs. *Nat Biotechnol*. 2019;37:540–6. [PubMed https://doi.org/10.1038/s41587-019-0072-8](https://doi.org/10.1038/s41587-019-0072-8)
5. nanoporetech/medaka: Sequence correction provided by ONT. 2022 [cited 2022 Aug 23]. <https://github.com/nanoporetech/medaka>
6. Warren RL, Coombe L, Mohamadi H, Zhang J, Jaquish B, Isabel N, et al. ntEdit: scalable genome sequence polishing. *Bioinformatics*. 2019;35:4430–2. [PubMed https://doi.org/10.1093/bioinformatics/btz400](https://doi.org/10.1093/bioinformatics/btz400)
7. Moshiri N. ViralMSA: massively scalable reference-guided multiple sequence alignment of viral genomes. *Bioinformatics*. 2021;37:714–6. [PubMed https://doi.org/10.1093/bioinformatics/btaa743](https://doi.org/10.1093/bioinformatics/btaa743)
8. Minh BQ, Schmidt HA, Chernomor O, Schrempf D, Woodhams MD, von Haeseler A, et al. IQ-TREE 2: new models and efficient methods for phylogenetic inference in the genomic era. *Mol Biol Evol*. 2020;37:1530–4. [PubMed https://doi.org/10.1093/molbev/msaa015](https://doi.org/10.1093/molbev/msaa015)
9. Lemoine F, Gascuel O. Gotree/Goalign: toolkit and Go API to facilitate the development of phylogenetic workflows. *NAR Genom Bioinform*. 2021 Sep;3:lqab075.
10. Isidro J, Borges V, Pinto M, Ferreira R, Sobral D, Nunes A, et al. First draft genome sequence of monkeypox virus associated with the suspected multi-country outbreak, May 2022. 2022 [cited 2022 May 30]. <https://virological.org/t/first-draft-genome-sequence-of-monkeypox-virus-associated-with-the-suspected-multi-country-outbreak-may-2022-confirmed-case-in-portugal/799>.

11. Isidro J, Borges V, Pinto M, Ferreira R, Sobral D, Nunes A, et al. Multi-country outbreak of Monkeypox virus: genetic divergence and first signs of microevolution. 2022 [cited 2022 Aug 17]. <https://virological.org/t/multi-country-outbreak-of-monkeypox-virus-genetic-divergence-and-first-signs-of-microevolution/806>
12. GenBank. Draft monkeypox virus genome from confirmed monkeypox case in Massachusetts, United States, May 2022. MPXV_USA_2022_MA001. 2022. <https://www.ncbi.nlm.nih.gov/nuccore/ON563414>
13. GenBank. First German genome sequence of monkeypox virus associated to multi-country outbreak in May 2022. MPXV-BY-IMB25241. 2022. <https://www.ncbi.nlm.nih.gov/nuccore/ON568298>

Appendix Table 1. Overview of samples collected from a patient for orthopoxvirus and monkeypox virus, Sweden, 2022*

Days after symptom onset	Sample	OPXV-PCR		MPXV-PCR	
		Result	Ct value	Result	Ct value
12	Swab from genital lesion	Pos‡	21.1	Pos	20.9
14	Swab from genital lesion	Pos	22.5	Pos	20.6
	EDTA-blood†	Neg		Pos¶	38.1
15	Swab from nasopharynx	Neg§		Pos¶	38.4
	Sputum	Pos	32.3	Pos	30.2
	Urine	Pos	28.8	Pos	26.8
	Saliva	Pos	35.1	Pos	33.0
18	Serum	Neg		Neg	
	Swab from nasopharynx	Pos	39.0	Pos	36.9
	Saliva/sputum	Pos	39.2	Pos	37.0
	Saliva/sputum	Pos	39.8	Pos	37.6
19	Swab from genital lesion	Pos	38.5	Pos	35.7
27	EDTA-blood	Neg		Neg	
	Swab from nasopharynx	Neg		Neg	
	Sputum	Pos	32.1	Pos	31.2
	Saliva	Pos	34.8	Pos	33.4
	Swab from genital lesion	Pos	38.9	Pos	35.0
	Swab from ruptured lymph node	Pos	22.5	Pos	20.6
40	EDTA-blood	Neg		Neg	
	Swab from nasopharynx	Neg		Neg	
	Saliva	Pos	28.3	Pos	25.8
	Urine	Neg		Neg	
	Swab from genital lesion	Neg		Neg	
	Swab from ruptured lymph node	Neg		Pos¶	36.8
	Semen	Neg		Pos¶	38.9
54	EDTA-blood	Not analyzed		Neg	
	Saliva	Not analyzed		Pos	35.0
	Swab from ruptured lymph node	Not analyzed		Neg	
	Swab from genital lesion	Not analyzed		Neg	
	Swab from nasopharynx	Not analyzed		Neg	
	Semen	Not analyzed		Pos	34.0
76	Saliva	Not analyzed		Pos	29.4

*Detection level for both viruses by real-time PCR is 40 Ct. Ct, cycle threshold; MPXV, monkeypox virus; Neg, negative; OPXV, orthopoxvirus; Pos, positive.

†Ethylenediaminetetraacetate–blood

‡Positive result.

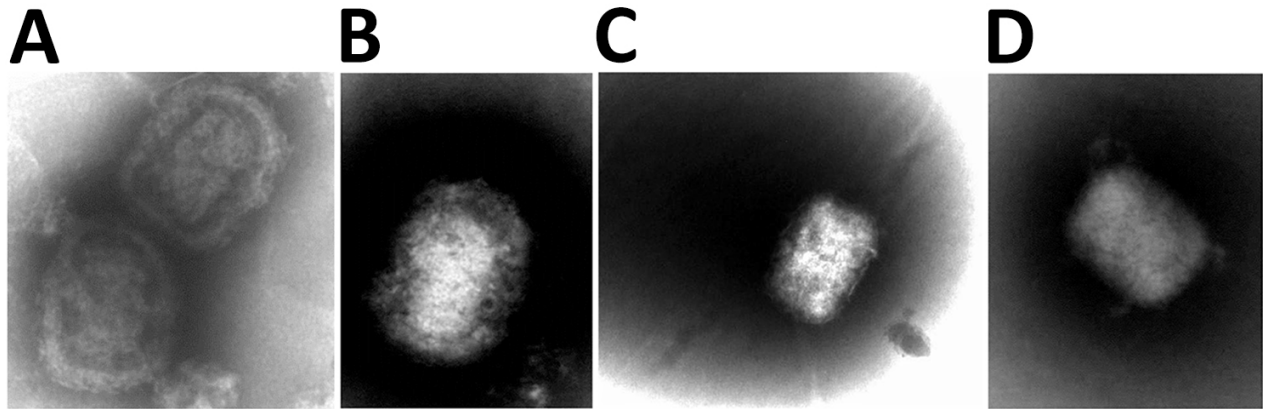
§Negative result.

¶Half the replicates tested positive.

Appendix Table 2. Primers and probes used in PCR testing of orthopoxvirus and monkeypox virus, Sweden, 2022*

Target	Sequence 5' to 3'	Reference
OPXV_Probe	TTTTCCAACCTAAATAGAACTTCATCGTTGYGTT- FAM-TAMRA	Modified from (1)
OPXV_Forward	GCCAGAGATATCATAGCCGCTC	
OPXV_Reverse	ACAAAGTTTGAACAAATAGAAAAGTGTTG	
MPXV_B21R_Probe	CCGTAATCCACTTCCT-FAM-MGB	
MPXV_B21R_Forward	GTCTACAGAGTCCAATCCTCCTCT	
MPXV_B21R_Reverse	TGTGGAGGAKAATAATCATCATGTT	

*MPXV, monkeypox virus; OPXV, orthopox virus.



Appendix Figure. Four electron-microscope images showing orthopoxvirus-like particles found in genital-lesion samples collected 12 days after symptom onset from patient with monkeypox, Sweden, 2022.