

## *Rickettsia mongolitimonae* Encephalitis, Southern France, 2018

María Dolores Corbacho Loarte, Cléa Melenotte,  
Nadim Cassir, Serge Cammilleri, Philippe  
Dory-Lautrec, Didier Raoult, Philippe Parola

Author affiliations: Hospital Universitario Severo Ochoa, Madrid, Spain (M.D. Corbacho Loarte); Institut Hospitalo-Universitaire–Méditerranée Infection, Marseille, France (M.D. Corbacho Loarte, C. Melenotte, N. Cassir, D. Raoult, P. Parola); Aix-Marseille University, Marseille (M.D. Corbacho Loarte, C. Melenotte, N. Cassir, D. Raoult, P. Parola); Assistance Publique des Hôpitaux de Marseille, Marseille (C. Melenotte, N. Cassir, S. Cammilleri, P. Dory-Lautrec, D. Raoult, P. Parola)

DOI: <https://doi.org/10.3201/eid2602.181667>

We report a case of *Rickettsia sibirica mongolitimonae* infection, an emerging tickborne rickettsiosis, with associated encephalitis in a 66-year-old man. Diagnosis was rapidly confirmed by quantitative PCR obtained from an eschar swab sample. The patient was successfully treated with oral doxycycline.

In July 2018, a 66-year-old man was admitted to the emergency department in Marseille, France, because of fever (40°C) and confusion. His medical history included arterial hypertension controlled with amlodipine and dyslipidemia and coronary artery disease treated with pravastatin and aspirin. He lived in a rural area near Marseille and owned dogs, pigs, pheasants, pigeons, and chickens. In the hospital emergency department, he received acyclovir (1 g every 8 h), amoxicillin (4 g every 6 h), and ceftriaxone (3 g every 12 h) for suspected meningoencephalitis.

At admission to the infectious diseases department, he had a general maculopapular rash over his trunk, palms of his hands, and soles of his feet of 3 days' duration (Figure, panel A). Blood pressure was 130/80 mm Hg. A 15-mm black eschar was noted on his right ankle, associated with rope-like lymphangitis (Figure, panel B). He had a 4/5 right corporal hemiparesis with hemisensory loss and right Babinski sign. Lumbar puncture results were unremarkable, and C-reactive protein was 65.4 mg/L (referent <3 mg/L). Oral doxycycline (300 mg 1×/d) was added to his drug regimen 3 days after symptom onset. Results of brain computed tomography scan were unremarkable. Magnetic resonance imaging showed multiple bilateral brain lesions compatible with acute encephalitis related to vasculitis (Figure, panel C). Positron emission tomographic

scan showed cerebral cortical diffuse hypometabolism (Appendix Figure, <https://wwwnc.cdc.gov/EID/article/26/2/18-1667-App1.pdf>). Results of microbiological tests performed on cerebrospinal fluid and indirect immunofluorescence assay for spotted fever group (SFG) rickettsiae were negative. DNA obtained from eschar swab samples was positive by quantitative PCR for all SFG *Rickettsia* species (*gltA* and *ompA* genes) (1). Positive samples tested with species-specific *R. massiliae*, *R. conorii*, and *R. sibirica mongolitimonae* primers were positive for *R. sibirica mongolitimonae* (35 cycles quantification) (1).

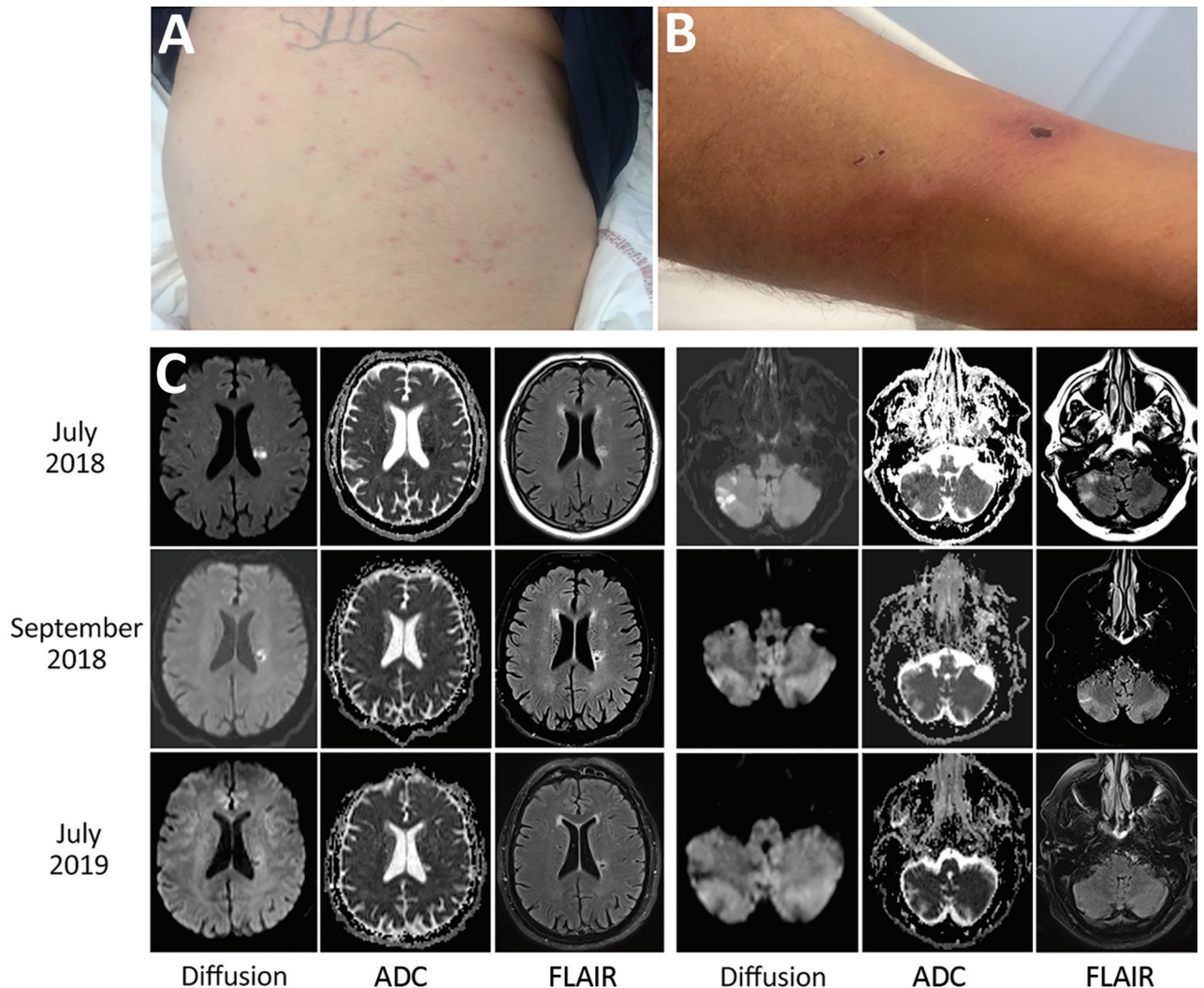
Oral doxycycline was continued for 10 days; other drugs were discontinued. The cutaneous lesions regressed at day 3, and neurologic symptoms progressively improved after administration of doxycycline. A low seroconversion for the SFG rickettsiae was observed (IgM 1:16; IgG 1:16) 3 weeks after symptom onset; at 7 weeks postinfection, serology became negative.

One month after symptom onset, the patient had 4/5 muscular strength in his right leg. Magnetic resonance imaging performed at 7 weeks and 1 year after symptom onset showed cerebral sequelae lesions (Figure, panel C). At 1 year, the Babinski sign in the right foot persisted, but muscular testing was 5/5 with the exception of lifting the right foot, which was 4/5.

*R. sibirica mongolitimonae* infection is an emerging rickettsiosis; <40 human cases have been described. It is seasonal in France (spring and summer). It has been referred to as lymphangitis-associated rickettsiosis because of the typical rope-like lymphangitis sign (2). Other clinical signs include the classic triad of fever, rash, and eschar. SENLAT (scalp eschar and neck lymphadenopathy after tick bite) also has been reported (3).

Most *R. sibirica mongolitimonae* infections have been reported in the Mediterranean area (France, Spain, Portugal, Greece, and Turkey), Africa (Algeria, Egypt, Cameroon, South Africa), and China (4,5). In Europe, vectors include the tick species *Hyalomma excavatum*, *H. marginatum*, *H. turanicum*, *Rhipicephalus pusillus*, *R. bursa*, and *Haemaphysalis parva* (1,2,4). *R. sibirica mongolitimonae* infection usually causes mild disease, but severe manifestations have been described, including retinal vasculitis, lethargy with hyponatremia, septic shock, myopericarditis, and acute renal failure (2,6).

Only *R. conorii conorii*, *R. rickettsii*, *R. japonica*, and *R. slovaca* have been associated with encephalitis in the literature (Appendix Table); no patients who had received doxycycline were reported to have died. Doxycycline has proven to be superior



**Figure.** Clinical manifestations and cerebral magnetic resonance imaging of a 66-year-old man with *Rickettsia sibirica mongolitimonae*-associated encephalitis, southern France, 2018. A) Maculopapular rash. B) Black eschar and rope-like lymphangitis on the right leg. C) Magnetic resonance imaging with diffusion (B1000), ADC, and FLAIR. In July 2018, cytotoxic lesions were observed intra-axially and in the white matter of right cerebellar hemispheres with FLAIR hypersignal and with low ADC signal. In September 2018, these cytotoxic lesions regressed in diffusion with the appearance of a necrotic cavity facing the roof of the left lateral ventricle. In July 2019, disappearance of diffusion anomalies. Small necrotic cavity with after-effects on FLAIR and ADC signals. ADC, apparent diffusion coefficient; FLAIR, fluid-attenuated inversion recovery.

to chloramphenicol and ciprofloxacin in rickettsial infection and should be the treatment of choice for rickettsial-associated encephalitis (1,7).

SFG rickettsiosis can be diagnosed by serology, culture, or molecular assay on blood, skin biopsy, or eschar swab sample. Seroconversion generally appears in the second and third weeks of illness; culture is fastidious and performed only in expert laboratories. Molecular tools using eschar cutaneous swab samples appeared as the best method for detecting and identifying *Rickettsia* spp. (1). The sensitivity of this technique is comparable with that of rickettsial detection on skin biopsy samples using molecular

tools. It is a noninvasive and nonpainful diagnostic method that can be performed easily where molecular facilities are available (3,8).

The discrepancy observed in this case between PCR and serology has been reported in cases of *R. africae* infection, in which seroconversion is delayed (28 days for IgG and 25 days for IgM) and doxycycline treatment within 7 days after symptom onset prevents development of antibodies (9,10). In this patient, we observed very low serologic response 3 weeks after symptom onset, which might have been affected by the early administration of doxycycline. Moreover, the lack of serologic response observed

here may be precisely related to the severity of the disease. The case we described illustrates the rapid efficacy of doxycycline to treat the severe neurologic consequences of rickettsial diseases, as well as the effectiveness and rapidity of the swab sample diagnostic test.

M.D.C.L. received a scholarship from SEIMC (Sociedad Española de Infecciosas y Microbiología Clínica) for a visiting fellowship at the Institut Hospitalo-Universitaire-Méditerranée Infection.

### About the Author

Dr. Corbacho Loarte is an internal medicine resident in Madrid and a visiting fellow at the Institut Hospitalo-Universitaire-Méditerranée Infection in Marseille. Her primary research interests are infectious disease, especially zoonoses, neglected tropical diseases, and migrant health.

### References

1. Rajoelison P, Mediannikov O, Javelle E, Raoult D, Parola P, Aoun O. *Rickettsia sibirica mongolitimonae* human infection: A diagnostic challenge. *Travel Med Infect Dis*. 2018;26:72-3. <http://dx.doi.org/10.1016/j.tmaid.2018.07.002>
2. Parola P, Paddock CD, Socolovschi C, Labruna MB, Mediannikov O, Kernif T, et al. Update on tick-borne rickettsioses around the world: a geographic approach. *Clin Microbiol Rev*. 2013;26:657-702. <http://dx.doi.org/10.1128/CMR.00032-13>
3. Solary J, Socolovschi C, Aubry C, Brouqui P, Raoult D, Parola P. Detection of *Rickettsia sibirica mongolitimonae* by using cutaneous swab samples and quantitative PCR. *Emerg Infect Dis*. 2014;20:716-8. <http://dx.doi.org/10.3201/eid2004.130575>
4. Kuscü F, Orkun O, Ulu A, Kurtaran B, Komur S, Inal AS, et al. *Rickettsia sibirica mongolitimonae* infection, Turkey, 2016. *Emerg Infect Dis*. 2017;23:1214-6. <http://dx.doi.org/10.3201/eid2307.170188>
5. Nouchi A, Monsel G, Jaspard M, Jannic A, Angelakis E, Caumes E. *Rickettsia sibirica mongolitimonae* infection in a woman travelling from Cameroon: a case report and review of the literature. *J Travel Med*. 2018;25:25. <http://dx.doi.org/10.1093/jtm/tax074>
6. Revilla-Martí P, Cecilio-Irazola Á, Gayán-Ordás J, Sanjoaquin-Conde I, Linares-Vicente JA, Oteo JA. Acute myopericarditis associated with tickborne *Rickettsia sibirica mongolitimonae*. *Emerg Infect Dis*. 2017;23:2091-3. <http://dx.doi.org/10.3201/eid2312.170293>
7. Gikas A, Doukakis S, Pediaditis J, Kastanakis S, Manios A, Tselentis Y. Comparison of the effectiveness of five different antibiotic regimens on infection with *Rickettsia typhi*: therapeutic data from 87 cases. *Am J Trop Med Hyg*. 2004;70:576-9. <http://dx.doi.org/10.4269/ajtmh.2004.70.576>
8. Morand A, Angelakis E, Ben Chaabane M, Parola P, Raoult D, Gautret P. Seek and Find! PCR analyses of skin infections in West-European travelers returning from abroad with an eschar. *Travel Med Infect Dis*. 2018;26:32-6. <http://dx.doi.org/10.1016/j.tmaid.2018.02.009>
9. Fournier P-E, Jensenius M, Laferl H, Vene S, Raoult D. Kinetics of antibody responses in *Rickettsia africae* and *Rickettsia conorii* infections. *Clin Diagn Lab Immunol*. 2002;9:324-8.
10. Jensenius M, Fournier P-E, Kelly P, Myrvang B, Raoult D. African tick bite fever. *Lancet Infect Dis*. 2003;3:557-64. [http://dx.doi.org/10.1016/S1473-3099\(03\)00739-4](http://dx.doi.org/10.1016/S1473-3099(03)00739-4)

Address for correspondence: Maria D. Corbacho Loarte, Aix Marseille University, IHU Méditerranée Infection, Faculté de Médecine Bd Jean Moulin, Marseille 13005, France; email: mdcorbacho@hotmail.com

## Human Alveolar Echinococcosis, Croatia

Davorka Dušek, Adriana Vince, Ivan Kurelac, Neven Papić, Klaudija Višković, Peter Deplazes, Relja Beck

Author affiliations: University Hospital for Infectious Diseases, Zagreb, Croatia (D. Dušek, A. Vince, I. Kurelac, N. Papić, K. Višković); University of Zagreb School of Medicine, Zagreb (D. Dušek, A. Vince, N. Papić); University of Zurich, Zurich, Switzerland (P. Deplazes); Croatian Veterinary Institute, Zagreb (R. Beck)

DOI: <https://doi.org/10.3201/eid2602.181826>

Alveolar echinococcosis is a parasitic disease caused by the tapeworm larval stage of *Echinococcus multilocularis*. This zoonotic disease has not been known to occur in Croatia. We report a confirmed case of human alveolar echinococcosis in a patient in Croatia who had never visited a known *E. multilocularis*-endemic area.

A 63-year-old male patient was sent to the University Hospital for Infectious Diseases in Zagreb, Croatia, in September 2017 for treatment of cystic liver lesions and pleural effusion. The patient had grown up and still lived in a rural area in Vukovar (45°21'N, 18°59'E/45.35°N, 18.99°E), where he worked for a waste management company. He spent free time in the woods picking mushrooms.

Before his referral, in November 2014, the patient underwent kidney ultrasonography, which also detected cystic formations in his liver. A subsequent multislice computed tomography (MSCT) scan in



# *Rickettsia mongolitimonae* Encephalitis, Southern France, 2018

## Appendix

**Appendix Table.** Encephalitis and *Rickettsia* spp.\*

Case	Epidemiologic data			Age/s ex	Previous illness	Clinical manifestation		CFS, CT scan, MRI	Diagnostic test	Treatment	Outcome	Ref
	Country	Rural	Date			General	Neurologic					
<i>Rickettsia conorii</i>												
1	Italy	NA	2013 Aug	78 y/F	Arterial hypertension, type 2 diabetes, stroke	Fe + R + S, renal failure	Coma GCS3	–CFS: meningitis –CT scan: normal –MRI: ND	IFA, ELISA	Chloramphenicol, levofloxacin, corticosteroids	Death	(1)
2	Portugal	Dogs	2010 Sep	59 y/M	None	Fe + R + S, myalgia	Headache, hemisensory loss	–CFS: no meningitis –CT scan: hypodensities frontal lobes and 1 lesion in left ventricle –MRI: multiple noncontrast enhancement, periventricular	IFA	Doxycycline 200 mg/12 h 4 d, doxycycline 100 mg/12 h 3 d	Hemisensory loss on the left	(2)
3	Morocco	Dogs	2009	1.2 y/M	None	Fe + R + S	Convulsions	–CFS: meningitis –CT scan: normal –MRI: normal	IFA	Josamycin 12 h, corticosteroids	Bilateral decreased vision, seizures	(3)
4	Spain	Dogs	2008 Jun	66 y/M	Type 2 diabetes	Fe + R + S, myalgia, renal failure, thrombocytopenia	Headache, confusion, quadriplegia, aphasia	–CFS: no meningitis –CT scan: normal –MRI: diffuse lesions in frontal, parietal, occipital, corpus callosum, cerebellar peduncles, pons, and limbic area	IFA	Doxycycline 100 mg/12 h 10 d	Aphasia and right hemiplegia	(4)
5	Morocco	NA	2004 Jul	49 y/F	None	Fe + R	Headache, confusion	–CFS: meningitis –CT scan: normal –MRI: meningeal contrast enhancement and lesion in right frontal lobe	IFA	Ceftriaxone, ampicillin, doxycycline	Remission	(5)

Case	Epidemiologic data			Age/s ex	Previous illness	Clinical manifestation		CFS, CT scan, MRI	Diagnostic test	Treatment	Outcome	Ref
	Country	Rural	Date			General	Neurologic					
6	India	Dogs	2009	4 y/F	None	Fe + R	Convulsions	–CFS: meningitis –CT scan: normal –MRI: ND	Weil-Felix, IFA	Chloramphenicol 75 mg/kg/d in 4 doses and doxycycline 2.2 mg/kg/12 h 10 d	Remission	(6)
7	Portugal	NA	2003 Summer	47 y/M	None	Fe + R + S, myalgia, renal failure, thrombo- cytopenia	Headache, convulsions, shock	–CFS: ND –CT scan: normal –MRI: ND	Immuno- histochemistry	None	Death	(7)
8	Spain	NA	2002	27 y/F	None	Fe, myalgia, nausea, abdominal pain	Headache, paresis on left side, convulsions	–CFS: no meningitis –CT scan: normal –MRI: contrast enhancement in the meninges and right parasyllian lesion	IFA	Valproate, clonazepam, ceftriaxon, acyclovir, doxycycline, phenobarbital, corticotherapy	Remission	(8)
9	Spain	None	1999 Jul	53 y/F	Adult celiac disease	Fe + R, myalgia, arthralgia, thrombo- cytopenia, hypotension	Confusion, paraplegia	–CFS: meningitis –CT scan: normal –MRI: lesions in left frontal lobe, cerebellar peduncles, and corpus callosum	IFA	Cefotaxime, acyclovir, isoniazid, rifampin, ethambutol, streptomycin, doxycycline, methylprednisolon e	Paraplegia	(9)
10	Spain	NA	1994 Summer	65 y/M	Type II diabetes	Fe + R + S, myalgia	Confusion, incontinence, ataxia	–CFS: meningitis. –CT scan: hypodensity in white matter –MRI: ND	IFA	Doxycycline 100 mg/12 h 7 d	Remission	(10)
11	Morocco	NA	1991 Jul	6 y/M	None	Fe + R + S, arthralgia	Confusion, convulsions	–CFS: meningitis. –CT scan: hypodensity in both internal capsules –MRI: ND	IFA	Thiamphenicol 15 d, corticosteroids 21 d	Mutism and quadriplegia	(11)
12	Spain	NA	1987 Summer	77 y/F	Arterial hypertension, type 2 diabetes	Fe + R + S, myalgia, renal failure, thrombo- cytopenia.	Headache, stupor, shock	–CFS: ND –CT scan: ND –MRI: ND	IFA	Amoxicillin 11 d, tetracycline 1 d	Death	(12)
13	France	Dogs	1984 Aug	20 d/F	None	Fe + R + S, hepatomegaly, splenomegaly, thrombo- cytopenia	Inactivity, convulsion	–CFS: meningitis –CT scan: ND –MRI: ND	IFA	Ampicillin, gentamicin, spiramycin	Death	(13)

Case	Epidemiologic data			Age/s ex	Previous illness	Clinical manifestation		CFS, CT scan, MRI	Diagnostic test	Treatment	Outcome	Ref
	Country	Rural	Date			General	Neurologic					
<i>Rickettsia japonica</i>												
14	Japan	Brushy vegetation	1992 Aug	58 y/M	NA	Fe + R + S, nausea vomiting	Confusion	–CFS: meningitis –CT scan: Normal –MRI: NA	IFA	Cefmetazole, clindamycin, aztreonam, imipenem, minocycline	Remission	(14)
15	Japan	Bamboo tree	1998 Apr	55 y/M	NA	Fe + R, myalgia, nausea, vomiting, renal failure, shock	Headache, confusion, convulsions	– CFS: meningitis –CT scan: subdural hematoma –MRI: NA	IFA	Panipenem, acyclovir, minocycline	Death	(15)
16	Japan	NA	Aug	77 y/M	NA	Fe + R + S	Confusion, convulsions	NA	IFA	Minocycline	Remission	(15)
17	Japan	NA	Aug	78 y/M	NA	Fe + R, thrombo- cytopenia	NA	NA	IFA	Minocycline	Remission	(15)
<i>Rickettsia slovaca</i>												
18	Slovakia	Garden	1978 May	33 y/F	None	Fe, myalgia, arthralgia, nausea, hepatomegaly	Headache, paresthesia, bradypsychia	–CFS: no meningitis –CT scan: ND –MRI: NA	IFA	Tetracycline, doxycycline	Minimum hemiparesia	(16)
<i>Rickettsia rickettsii</i>												
19	USA	Dog, horses, chickens, parrots, rats, mice	1993 Aug	45 y/F	None	Fe + R + S, myalgia, thrombo- cytopenia	Confusion, convulsions, disorientation	–CFS: no meningitis –CT scan: white matter hypodensity and diffuse cerebral edema –MRI: multiple punctata area of increased signal through cerebral white matter	IFA	Imipenem, doxycycline	Remission	(17)
20	USA	NA	1997	68 y/M	None	Fe + R, thrombo- cytopenia	Confusion, disorientation	–CFS: no meningitis –CT scan: normal –MRI: symmetrical zones of hyperintensity in periventricular white matter	IFA	Doxycycline	Attentional deficits, visuospatial difficulties and global impairment in memory	(18)
21	USA	Farm	1999	7 y/M	None	Fe + R + S, myalgia, arthralgia	Headache, lethargy, convulsions	–CFS: meningitis –CT scan: NA –MRI: multiple foci of hyperintensity in white matter	IFA	Doxycycline, methylprednisolone	Deficit in short-term memory	(19)
22	USA	NA	2016 Apr	15 y/F	None	Fe + R	Convulsions	–CFS: NA –CT scan: NA	IFA	Doxycycline	Speech difficulty	(20)

Case	Epidemiologic data			Age/s ex	Previous illness	Clinical manifestation		CFS, CT scan, MRI	Diagnostic test	Treatment	Outcome	Ref
	Country	Rural	Date			General	Neurologic					
23	USA	Dog, cat	1997 Jun	43 y/F	None	Fe + R + S, occipital lymph node, thrombo- cytopenia, respiratory distress, acute myocardial infarction	Headache, confusion, aphasia, tetraparesia	–MRI: multiple foci of hyperintensity in periventricular white matter –CFS: meningitis –CT scan: diffuse cerebral edema with cerebellar herniation –MRI: NA	IFA	Ceftriaxone, doxycycline, methylprednisolon e	Death	(21)
24	USA	NA	2015 Jun	7 y/F	None	Fe + R + S, thrombo- cytopenia, renal failure, respiratory distress	Headache, disorientation , aphasia, dystonic posture	–CFS: no meningitis –CT scan: diffuse supratentorial attenuation –MRI: diffuse hyperintense lesion in white matter	IFA	Ceftriaxone, vancomycin, doxycycline	Aphasia	(22)

\*CSF, cerebrospinal fluid; CT, computed tomographic; Fe: fever, GCS: Glasgow coma score; CT: computed tomography ; MRI: magnetic resonance imaging ; NA: not available; IFA, immunofluorescence assay; NA, not available; ND, not done; R, rash; ref, reference; S, scar.

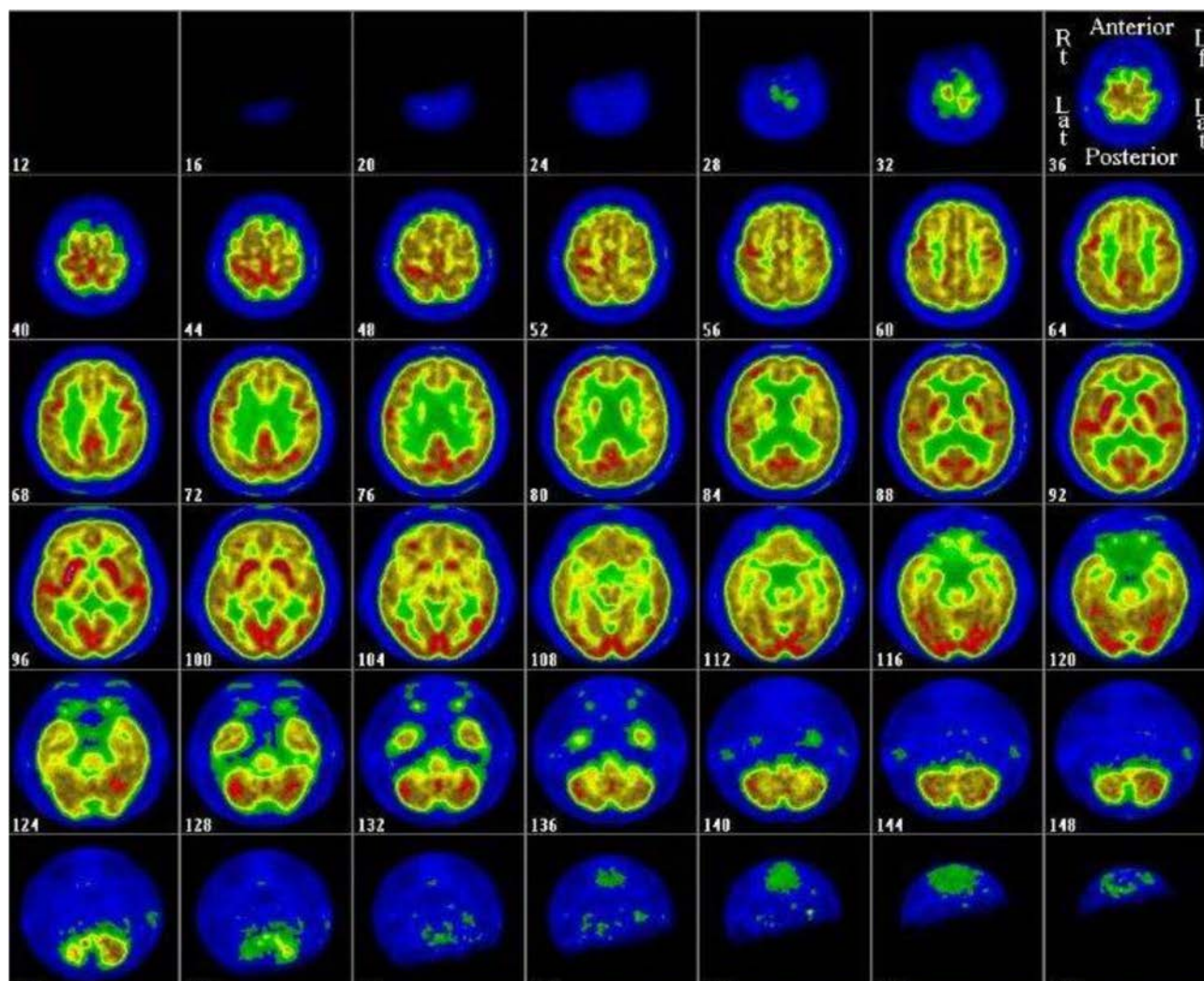
## References

1. Colomba C, Imburgia C, Trizzino M, Titone L. First case of Mediterranean spotted fever-associated rhabdomyolysis leading to fatal acute renal failure and encephalitis. *Int J Infect Dis.* 2014;26:12–3. [PubMed http://dx.doi.org/10.1016/j.ijid.2014.01.024](http://dx.doi.org/10.1016/j.ijid.2014.01.024)
2. Duque V, Ventura C, Seixas D, Barai A, Mendonça N, Martins J, et al. Mediterranean spotted fever and encephalitis: a case report and review of the literature. *J Infect Chemother.* 2012;18:105–8. [PubMed http://dx.doi.org/10.1007/s10156-011-0295-1](http://dx.doi.org/10.1007/s10156-011-0295-1)
3. Bougteba A, Basir A, Charradi N. Meningoencephalitis caused by *Rickettsia conorii* in a young infant [in French]. *Rev Neurol (Paris).* 2011;167:173–6. [PubMed http://dx.doi.org/10.1016/j.neurol.2010.07.010](http://dx.doi.org/10.1016/j.neurol.2010.07.010)
4. Aliaga L, Sánchez-Blázquez P, Rodríguez-Granger J, Sampedro A, Orozco M, Pastor J. Mediterranean spotted fever with encephalitis. *J Med Microbiol.* 2009;58:521–5. [PubMed http://dx.doi.org/10.1099/jmm.0.004465-0](http://dx.doi.org/10.1099/jmm.0.004465-0)
5. Demeester R, Claus M, Hildebrand M, Vlieghe E, Bottieau E. Diversity of life-threatening complications due to Mediterranean spotted fever in returning travelers. *J Travel Med.* 2010;17:100–4. [PubMed http://dx.doi.org/10.1111/j.1708-8305.2009.00391.x](http://dx.doi.org/10.1111/j.1708-8305.2009.00391.x)
6. Tikare NV, Shahapur PR, Bidari LH, Mantur BG. Rickettsial meningoencephalitis in a child—a case report. *J Trop Pediatr.* 2010;56:198–200. [PubMed http://dx.doi.org/10.1093/tropej/fmp065](http://dx.doi.org/10.1093/tropej/fmp065)
7. Amaro M, Bacellar F, França A. Report of eight cases of fatal and severe Mediterranean spotted fever in Portugal. *Ann N Y Acad Sci.* 2003;990:331–43. [PubMed http://dx.doi.org/10.1111/j.1749-6632.2003.tb07384.x](http://dx.doi.org/10.1111/j.1749-6632.2003.tb07384.x)
8. Parra-Martínez J, Sancho-Rieger J, Ortiz-Sánchez P, Peset V, Brocalero A, Castillo A, et al. Encephalitis caused by *Rickettsia conorii* without exanthema [in Spanish]. *Rev Neurol.* 2002;35:731–4. [PubMed](http://dx.doi.org/10.1016/j.neurol.2002.07.010)
9. Ezpeleta D, Muñoz-Blanco JL, Taberner C, Giménez-Roldán S. Neurological complications of Mediterranean boutonuse fever. Presentation of a case of acute encephalomyelitis and review of the literature [in Spanish]. *Neurologia.* 1999;14:38–42. [PubMed](http://dx.doi.org/10.1016/j.neurol.1999.01.010)



10. Marcos Dolado A, Sánchez Portocarrero J, Jiménez Madridejo R, Pontes Navarro JC, García Urrea D. Meningoencephalitis due to *Rickettsia conorii*. Etiopathological, clinical and diagnostic aspects [in Spanish]. *Neurologia*. 1994;9:72–5. [PubMed](#)
11. Benhammou. Fièvre Boutonneuse Méditerranéenne révélée par une atteinte neurologique grave. *Archives Francaises Pédiatriques*. 1991;48:635–6.
12. Walker GA, Masters KS, Shah DN, Anseth KS, Leinwand LA. Valvular myofibroblast activation by transforming growth factor-beta: implications for pathological extracellular matrix remodeling in heart valve disease. *Circ Res*. 2004;95:253–60. [PubMed](#)  
<http://dx.doi.org/10.1161/01.RES.0000136520.07995.aa>
13. Texier P, Rousselot JM, Quillerou D, Aufrant C, Robain D, Foucaud P. Fièvre boutonneuse méditerranéenne: à propos d'un cas mortel chez un nouveau-né. *Archives Francaises Pédiatriques*. 1984;41:51–3.
14. Araki M, Takatsuka K, Kawamura J, Kanno Y. Japanese spotted fever involving the central nervous system: two case reports and a literature review. *J Clin Microbiol*. 2002;40:3874–6. [PubMed](#) <http://dx.doi.org/10.1128/JCM.40.10.3874-3876.2002>
15. Kodama K, Senba T, Yamauchi H, Nomura T, Chikahira Y. Clinical study of Japanese spotted fever and its aggravating factors. *J Infect Chemother*. 2003;9:83–7. [PubMed](#) <http://dx.doi.org/10.1007/s10156-002-0223-5>
16. Mittermayer T, Brezina R, Urvölgyi J. First report of an infection with *Rickettsia slovaca*. *Folia Parasitol (Praha)*. 1980;27:373–6. [PubMed](#)
17. Baganz MD, Dross PE, Reinhardt JA. Rocky Mountain spotted fever encephalitis: MR findings. *AJNR Am J Neuroradiol*. 1995;16(Suppl):919–22. [PubMed](#)
18. Bergeron JW, Braddom RL, Kaelin DL. Persisting impairment following Rocky Mountain spotted fever: a case report. *Arch Phys Med Rehabil*. 1997;78:1277–80. [PubMed](#) [http://dx.doi.org/10.1016/S0003-9993\(97\)90345-2](http://dx.doi.org/10.1016/S0003-9993(97)90345-2)
19. Wei TY, Baumann RJ. Acute disseminated encephalomyelitis after Rocky Mountain spotted fever. *Pediatr Neurol*. 1999;21:503–5. [PubMed](#)  
[http://dx.doi.org/10.1016/S0887-8994\(99\)00028-4](http://dx.doi.org/10.1016/S0887-8994(99)00028-4)

20. Wittler RR, Minns GO. An adolescent with fever, rash, and altered mental status. *Clin Infect Dis*. 2016;62:1610–1. [PubMed](#)  
<http://dx.doi.org/10.1093/cid/ciw096>
21. Samuels MA, Newell KL. Case records of the Massachusetts General Hospital. Weekly clinicopathological exercises. Case 32-1997. A 43-year-old woman with rapidly changing pulmonary infiltrates and markedly increased intracranial pressure. *N Engl J Med*. 1997;337:1149–56. [PubMed](#)  
<http://dx.doi.org/10.1056/NEJM199710163371608>
22. Sun LR, Huisman TAGM, Yeshokumar AK, Johnston MV. Ongoing cerebral vasculitis during treatment of Rocky Mountain spotted fever. *Pediatr Neurol*. 2015;53:434–8. [PubMed](#) <http://dx.doi.org/10.1016/j.pediatrneurol.2015.07.003>



**Appendix Figure.** PET scan imaging showing a cerebral cortical diffuse hypometabolism.