

## Routine Culture–Resistant *Mycobacterium tuberculosis* Rescue and Shell-Vial Assay, France

Mustapha Fellag, Jamal Saad, Nicholas Armstrong, Eric Chabrière, Carole Eldin, Jean-Christophe Lagier, Michel Drancourt

Author affiliations: Institut Hospitalier Universitaire Méditerranée Infection, Marseille, France (M. Fellag, J. Saad); Aix-Marseille University, Marseille (M. Fellag, J. Saad, N. Armstrong, E. Chabrière, C. Eldin, J.-C. Lagier, M. Drancourt)

DOI: <https://doi.org/10.3201/eid2511.190431>

We used shell-vial assay with a medium that buffered rifampin to isolate routine culture–resistant *Mycobacterium tuberculosis* bacteria from cerebrospinal fluid and rifampin-containing intervertebral disc and vertebral corpus of a patient in treatment for Pott's disease and disseminated tuberculosis. Whole-genome sequencing confirmed *M. tuberculosis* lineage 4 (Euro-American) strain.

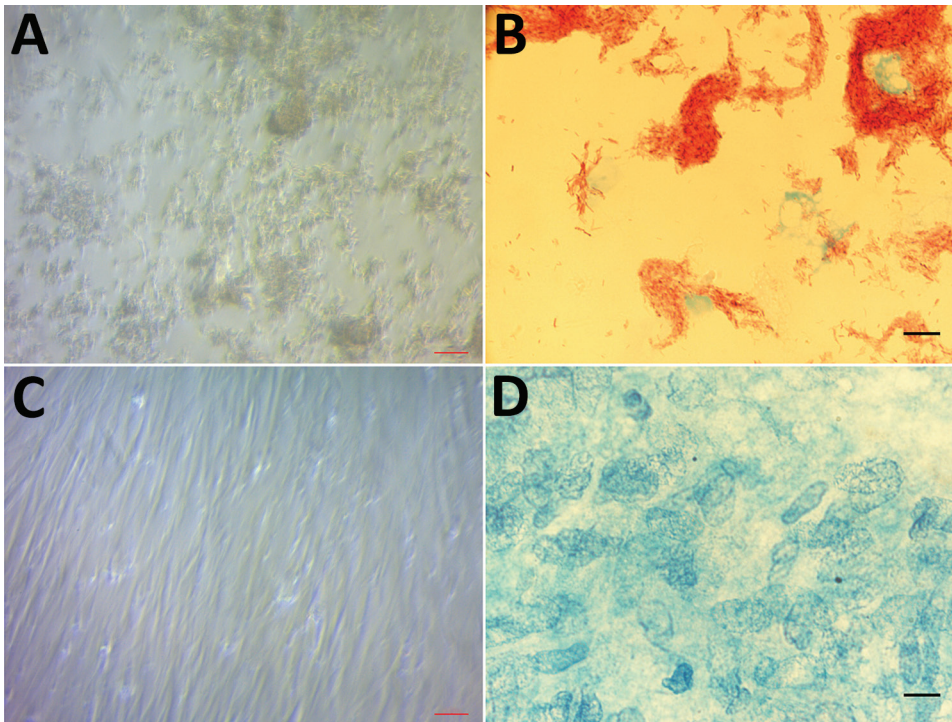
Culturing *Mycobacterium tuberculosis* from clinical specimens confirms the viability of mycobacteria and enables drug susceptibility testing (1). Routinely used culture protocols may fail to isolate *M. tuberculosis* from vertebral biopsy specimens in 17%–50% of cases (2) and from cerebrospinal fluid (CSF) specimens in >80% of cases (3). However, the shell-vial culture assay (4) has demonstrated a high sensitivity for the isolation of mycobacteria, representing an alternative method for growing *M. tuberculosis* (5,6).

We report a case of disseminated tuberculosis (TB) documented by culturing *M. tuberculosis* strain P7739 from a patient who was previously treated with antituberculous drugs. We used the shell-vial assay, even though strain P7739 resisted standard cell-free culture techniques. The Ethics Committee of Institut Hospitalier Universitaire Méditerranée Infection (Marseille, France) approved this study (no. 2016-024, October 19, 2016).

A 47-year-old man who was HIV negative and had no previous history of TB received a diagnosis of Pott's disease with systemic tuberculosis on the basis of clinical symptoms of spondylodiscitis, myelitis, meningitis, and pulmonary miliary infection. In January 2017, the patient suffered lumbar pain; a computer tomodensitometry scan showed corporeal bone defects in the L1 vertebra. Ten months later, magnetic resonance imaging revealed T12–L1 vertebral spondylodiscitis with a paravertebral abscess

in the right iliopsoas muscle. We performed 2 biopsies of the vertebral corpus of T12 and L1 and 1 biopsy of the intervertebral disc; we also collected CSF and sputum. These clinical specimens remained negative for *M. tuberculosis* using microscopic examination after Ziehl-Neelsen staining, real-time PCR (GenExpert, <https://www.cepheid.com>), culture in liquid medium BBL Mycobacteria Growth Indicator Tube (Becton Dickinson, <https://www.bd.com>), and in solid culture media including Coletsos medium (bioMérieux, <https://www.biomerieux.com>). Thirteen days later, the neurologic condition of the patient deteriorated with meningeal syndrome. Examination by magnetic resonance imaging showed a triventricular hydrocephalus and transependymal periventricular resorption, which led to an emergency external ventricular bypass. We strongly suspected TB, so we introduced TB treatment (900 mg rifampin, 300 mg isoniazid, 1,800 mg pyrazinamide, and 1,200 mg ethambutol daily). We performed a second round of clinical sampling from bronchoalveolar fluid, T12 vertebral corpus and T12–L1 intervertebral discs, and CSF 9 days after the initiation of TB treatment. Microscopic examination after Ziehl-Neelsen staining remained negative, as did results from the GenExpert assay, except for the detection of a rifampin-susceptible *M. tuberculosis* complex mycobacterium in 3 vertebral biopsy specimens and the intervertebral disc specimen. Culturing in MGIT tubes and on Coletsos remained negative after 8 weeks of incubation.

We inoculated 5 samples (1 CSF, 3 bone biopsy, 1 intervertebral disc) on human embryonic lung (HEL) fibroblasts (HEL 299 ATCC CCL-137; American Type Culture Collection, <https://www.lgcstandards-atcc.org>) using the shell-vial assay incorporating negative controls, as described previously (6). After 17–28 days of incubation, negative control vials remained sterile, whereas these 5 inoculated cell cultures grew Ziehl-Neelsen–positive mycobacteria (Figure). Seven-day subculture on Coletsos medium yielded colonies identified as *M. tuberculosis* strain P7739 by matrix-assisted laser desorption/ionization time-of-flight mass spectrometry (7). In vitro susceptibility assays indicated susceptibility to rifampin, ethambutol, chloramphenicol, clofazimine, and trimethoprim/sulfamethoxazole and resistance to minocycline and pyrazinamide (8). The genome sequence of *M. tuberculosis* strain P7739 (1 scaffold with 4,392,478 bp and 64.8% guanine-cytosine content) mapped more closely with *M. tuberculosis* Erdman (GenBank accession no. NC\_020559.1) using CLC Genomics version 7 (<https://www.qiagenbioinformatics.com>). Annotation using Prokka version 1.12 (<https://github.com/tseemann/prokka>) yielded 4,171 protein-coding genes, 2 repeat regions, and 55 RNA genes (51 tRNA, 3 rRNA, and 1 tmRNA). Single-nucleotide polymorphism (SNP) comparison with different lineages at the core genome level using TB profiler



**Figure.** Light microscopic examination of human embryonic lung cells inoculated for 28 days from a clinical sample from a 47-year-old man with Pott's disease and systemic tuberculosis, France. A) Cytopathic effect consisting of cell lysis caused by growing *Mycobacterium tuberculosis*. Original magnification  $\times 200$ . B) *M. tuberculosis* mycobacteria observed after Ziehl-Neelsen staining. Original magnification  $\times 1,000$ , by oil immersion. C) Absence of any cytopathic effect in negative control cell culture. Original magnification  $\times 200$ . D) Absence of any mycobacteria in the negative control cell culture after Ziehl-Neelsen staining. Original magnification  $\times 1,000$  by oil immersion.

(<http://tbd.r.lshmt.ac.uk>) indicated that strain P7739 (GenBank accessionno.CAABOY01000000) was related to *M. tuberculosis* lineage 4 and did not encode for antimicrobial resistance-associated mutations.

We isolated *M. tuberculosis* strain P7739 from this patient using the shell-vial assay 9 days after initiation of TB treatment. Liquid chromatography mass spectrometry (LC/MS) (Acquity I-Class Vion-IMS Q-ToF, Waters, <https://www.waters.com>) detected 0.45  $\mu\text{g}$  rifampin/g in the intervertebral disc specimen and 0.04  $\mu\text{g}$  rifampin/g in the 2 vertebral bone biopsy specimens; 1 exhibited anti-TB activity. Further dosage with rifampin at 0, 7, and 14 days postincubation with HEL revealed that 80% of the amount of free rifampin was lost at day 14 (Appendix Figure, <https://wwwnc.cdc.gov/EID/article/25/11/19-0431-App1.pdf>).

Gouriet et al. reported that 11.5% of *Mycobacterium* sp. isolates are cultured only in a cell culture assay (6). We cultured *M. tuberculosis* using the shell-vial assay after incubating for 17–28 days, in accordance with previous studies (5). Our findings confirm the use of the shell-vial assay in diagnosis of tuberculosis in patients in whom TB is suspected and whose specimens do not grow on conventional media, especially after initiating TB treatment in patients before sampling. Our observations suggest that cell culture medium buffers the anti-TB activity of clinical specimens, thus enabling growth of *M. tuberculosis* mycobacteria that are no longer exposed to anti-TB activity.

This work was supported by the Government of France under the “Investissements d’Avenir” (Investments for the Future) program managed by the National Agency for Research (Méditerranée Infection 10-IAHU-03) and by the Région Provence Alpes Côte d’Azur and European funding FEDER IHUBIOTK.

### About the Author

Dr. Fellag is a veterinarian and a PhD candidate at Aix-Marseille University, Marseille, France. His research interests include the diagnosis and the natural history of tuberculosis in humans and animals.

### References

1. Asmar S, Drancourt M. Rapid culture-based diagnosis of pulmonary tuberculosis in developed and developing countries. *Front Microbiol.* 2015 [cited 2018 Oct 10]. <https://www.frontiersin.org/articles/10.3389/fmicb.2015.01184/full>
2. Colmenero JD, Ruiz-Mesa JD, Sanjuan-Jimenez R, Sobrino B, Morata P. Establishing the diagnosis of tuberculous vertebral osteomyelitis. *Eur Spine J.* 2013;22(Suppl 4):579–86. <https://doi.org/10.1007/s00586-012-2348-2>
3. Modi M, Sharma K, Prabhakar S, Goyal MK, Takkar A, Sharma N, et al. Clinical and radiological predictors of outcome in tubercular meningitis: a prospective study of 209 patients. *Clin Neurol Neurosurg.* 2017;161:29–34. <https://doi.org/10.1016/j.clineuro.2017.08.006>
4. Marrero M, Raoult D. Centrifugation-shell vial technique for rapid detection of Mediterranean spotted fever rickettsia in blood culture. *Am J Trop Med Hyg.* 1989;40:197–9. <https://doi.org/10.4269/ajtmh.1989.40.197>
5. Fournier P-E, Drancourt M, Lepidi H, Gevaudan M-J, Raoult D. Isolation of mycobacteria from clinical samples using the

- centrifugation-shell vial technique. *Eur J Clin Microbiol Infect Dis*. 2000;19:69–70. <https://doi.org/10.1007/s100960050015>
6. Gouriet F, Fenollar F, Patrice J-Y, Drancourt M, Raoult D. Use of shell-vial cell culture assay for isolation of bacteria from clinical specimens: 13 years of experience. *J Clin Microbiol*. 2005;43:4993–5002. <https://doi.org/10.1128/JCM.43.10.4993-5002.2005>
  7. Zingue D, Flaudrops C, Drancourt M. Direct matrix-assisted laser desorption ionisation time-of-flight mass spectrometry identification of mycobacteria from colonies. *Eur J Clin Microbiol Infect Dis*. 2016;35:1983–7. <https://doi.org/10.1007/s10096-016-2750-5>
  8. Bouzid F, Astier H, Osman DA, Javelle E, Hassan MO, Simon F, et al. Extended spectrum of antibiotic susceptibility for tuberculosis, Djibouti. *Int J Antimicrob Agents*. 2018;51:235–8. <https://doi.org/10.1016/j.ijantimicag.2017.07.007>

---

Address for correspondence: Michel Drancourt, MEPHI, IHU Méditerranée Infection, 19-21 Boulevard Jean Moulin, 13005 Marseille, France; email: [michel.drancourt@univ-amu.fr](mailto:michel.drancourt@univ-amu.fr)

---

## Molecular Epidemiology of Hantaviruses in the Czech Republic

**Hana Zelena, Petra Strakova, Marta Heroldova, Jakub Mrazek, Tomas Kastl, Alena Zakovska, Daniel Ruzek, Jan Smetana, Ivo Rudolf**

Author affiliations: Institute of Public Health in Ostrava, Ostrava, Czech Republic (H. Zelena, J. Mrazek); University of Defence, Hradec Kralove, Czech Republic (H. Zelena, J. Smetana); The Czech Academy of Sciences, Brno, Czech Republic (P. Strakova, M. Heroldova, I. Rudolf); Veterinary Research Institute, Brno (P. Strakova, T. Kastl, D. Ruzek); Mendel University, Brno (M. Heroldova); Masaryk University, Brno (A. Zakovska); Biology Centre of the Czech Academy of Sciences, Ceske Budejovice, Czech Republic (D. Ruzek)

DOI: <https://doi.org/10.3201/eid2511.190449>

During 2008–2018, we collected samples from rodents and patients throughout the Czech Republic and characterized hantavirus isolates. We detected Dobrava-Belgrade and Puumala orthohantaviruses in patients and Dobrava-Belgrade, Tula, and Seewis orthohantaviruses in rodents. Increased knowledge of eco-epidemiology of hantaviruses will improve awareness among physicians and better outcomes of patients.

The most prevalent hantaviruses in Europe are Tula virus, Puumala virus (PUUV), and Dobrava-Belgrade virus (DOBV), all orthohantaviruses; PUUV and DOBV cause hemorrhagic fever with renal syndrome (1). Four DOBV genotypes of different virulences in humans are known: the nonpathogenic Saaremaa; Kurkino, which causes mostly mild disease; and Dobrava and Sochi, which are both highly pathogenic (2).

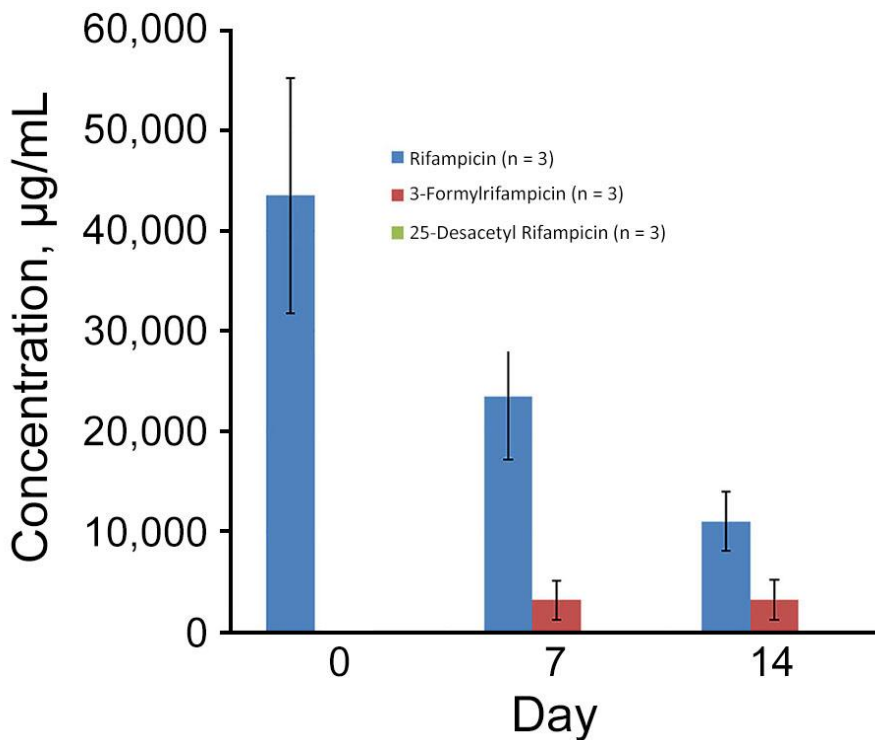
Tula virus is the most frequently detected hantavirus in rodents in the Czech Republic, followed by PUUV in Moravia and DOBV in South Bohemia. The seroprevalence of hantaviruses in humans in the Czech Republic is 1%–1.4% (3). In 2009, one case of DOBV infection in a hospitalized patient was reported in the Czech Republic (4), and in 2011, two more occurred at the Czech Republic–Slovakia border (5); in 2017, a fatal DOBV case was reported (6). All 4 of these cases were classified as Dobrava genotype by PCR and sequencing. Overall, 82 hantavirus infections were reported in humans in the Czech Republic during 2008–2017 (7). In this study, we aimed to determine the location of DOBV reservoirs in the Czech Republic and molecularly characterize positive samples.

During 2010–2017, we collected 1,551 wild rodents from different locations of the Czech Republic: 618 yellow-necked mice (*Apodemus flavicollis*), 37 wood mice (*A. sylvaticus*), 222 striped field mice (*A. agrarius*), 445 bank voles (*Myodes glareolus*), 40 common voles (*Microtus arvalis*), and 189 field voles (*Microtus agrestis*). We trapped all rodents as specified by the Animal Protection Act No. 246/1992 of the Czech Republic. Moreover, we obtained 61 clinical samples acquired from patients with hantavirus infections during 2008–2018; these hantavirus diagnoses were based on serologic testing (detection of hantavirus-specific IgG and IgM) and clinical and laboratory findings (fever, renal dysfunction, thrombocytopenia).

We tested human serum samples by Anti-Hantavirus Pool 1 “Eurasia” ELISA (IgG and IgM) and confirmed previous hantavirus results by immunoblot EUROLINE Anti-Hanta Profile 1 (IgG and IgM) (both Euroimmun, <https://www.euroimmun.com>). We isolated RNA from rodent lung samples and human serum, plasma, and whole blood samples using QIAamp Viral RNA Kit (QIAGEN, <https://www.qiagen.com>) and QIAzol (QIAGEN) or TRIzol (Invitrogen, <https://www.thermofisher.com>). We screened rodent and human RNA samples for hantavirus RNA using a reverse transcription PCR that amplified a 390-bp fragment of the large (L) segment (8). We tested L segment–positive samples with additional PCRs targeting regions of the medium (M) and small (S) segments (4). We analyzed hantavirus sequences using BLAST (<https://blast.ncbi.nlm.nih.gov/Blast.cgi>), aligned with BioEdit (9), and built phylogenetic trees using MEGA 7.0 (<https://megasoftware.net>).

# Routine Culture–Resistant *Mycobacterium tuberculosis* Rescue and Shell-Vial Assay, France

## Appendix



**Appendix Figure.** Ion response of free rifampin and its human metabolites measured over 14 days by liquid chromatography mass spectrometry in the supernatant of HEL cells. Bars indicate the standard deviation (n = 3) for each metabolite.