

9. Tong XC, Weng SS, Xue F, Wu X, Xu TM, Zhang WH. First human infection by a novel avian influenza A(H7N4) virus. *J Infect*. 2018;77:249–57. <https://doi.org/10.1016/j.jinf.2018.06.002>
10. World Health Organization. Human infection with avian influenza A(H7N4) virus—China. *Disease Outbreak News (DON)* 2018 [cited 2018 Dec 17]. <https://www.who.int/csr/don/22-february-2018-ah7n4-china>

Address for Correspondence: Erik A. Karlsson, Institut Pasteur du Cambodge Virology Unit, 5 Monivong Blvd, PO Box 983, Phnom Penh, Cambodia; email: ekarlsson@pasteur-kh.org

***Mycobacterium marseillense* Infection in Human Skin, China, 2018**

Bibo Xie,¹ Yanqing Chen,¹ Jian Wang, Wei Gao, Haiqing Jiang, Jiya Sun, Xindong Jin, Xudong Sang, Xiaobing Yu, Hongsheng Wang

Author affiliations: Institute of Dermatology, Chinese Academy of Medical Sciences and Peking Union Medical College, Nanjing, China (B. Xie, Y. Chen, W. Gao, H. Jiang, H. Wang); Zhejiang Institute of Dermatology, Deqing, China (B. Xie, J. Wang, X. Jin, X. Sang, X. Yu); Jiangsu Key Laboratory of Molecular Biology for Skin Diseases and STIs, Nanjing (Y. Chen, W. Gao, H. Jiang, H. Wang); Suzhou Institute of Systems Medicine, Chinese Academy of Medical Sciences, Suzhou, China (J. Sun); Centre for Global Health, Nanjing Medical University, Nanjing (H. Wang)

DOI: <https://doi.org/10.3201/eid2510.190695>

We describe a case of facial skin infection and sinusitis caused by *Mycobacterium marseillense* in an immunocompetent woman in China in 2018. The infection was cleared with clarithromycin, moxifloxacin, and amikacin. Antimicrobial drug treatments could not be predicted by genetic analyses; further genetic characterization would be required to do so.

Mycobacterium marseillense is a member of the *M. avium* complex (1) that has caused infections with lymphatic or pulmonary involvement sporadically in humans (2–4). We report *M. marseillense* infection involving facial skin in an immunocompetent woman in eastern China.

¹These authors contributed equally to this article.

In April 2018, a 59-year-old woman was referred to our institute (Institute of Dermatology, Chinese Academy of Medical Sciences and Peking Union Medical College, Nanjing, China) for a 4-year history of an erythematous plaque with ulceration located on the right cheek. The primary lesion was a small erythematous patch that gradually developed into an asymptomatic ulcerative plaque (i.e., the plaque had no heat, swelling, pain, or pruritus). She also reported occasional bloody, purulent nasal discharge over the course of 2 years. Two years before visiting our hospital, cutaneous tuberculosis was suspected, so she received treatment for tuberculosis (rifampin, isoniazid, ethambutol, pyrazinamide) for 10 months. No obvious improvement was observed with this treatment. Her medical history was otherwise unremarkable.

On physical examination, an infiltrated erythematous plaque with yellow scales and crusts on the right cheek was visible (Figure, panel A). Routine laboratory tests showed no remarkable findings. The results of autoantibody and HIV tests were negative, and immune subset cell counts were unremarkable. Histologic examination showed infiltration of a large number of lymphocytes, plasma cells, and neutrophils and some tissue cells in the dermis (Appendix Figure 1, <https://wwwnc.cdc.gov/EID/article/25/10/19-0695-App1.pdf>). Computed tomography scan of the paranasal sinuses showed bilateral maxillary, right ethmoid, and frontal sinusitis (Figure, panel C). Culture and PCR for mycobacteria in nasal discharge yielded negative findings.

After 3 weeks of skin tissue culture at 32°C in Löwenstein–Jensen medium, we observed smooth, yolk-yellow bacterial colonies (Appendix Figure 2). Ziehl–Neelsen staining confirmed the cultured organism was acid-fast bacilli. Sequence analysis indicated that the complete genetic sequence of 16S rRNA was 99.0%, *hsp65* 100%, and *rpoB* 99.8% homologous with *M. marseillense* strain FLAC0026. Phylogenetic analysis of the 16S rRNA sequence showed the isolate clustered with *M. chimaera* and *M. intracellulare* (Figure, panel D). Although the 16S rRNA gene sequence of the isolate was 100% similar to *M. intracellulare* subsp. *yongonense* 05-1390, the sequence similarities to *hsp65* and *rpoB* were relatively low. Sequence analyses suggested *M. marseillense* infection.

Referring to the guidelines for pulmonary *M. avium* complex disease, we treated the patient with the antimicrobial drugs clarithromycin, rifampin, and ethambutol (5). Afterward, in vitro drug susceptibility testing showed the isolate was sensitive to clarithromycin, azithromycin, and amikacin; moderately sensitive to moxifloxacin; and resistant to ethambutol and rifampin. Therefore, 3 months after initiating treatment, we changed the regimen to clarithromycin, moxifloxacin, and amikacin, which she received for 2 months. The patient's skin lesions healed gradually, and nasal symptoms disappeared, but a scar and erythema

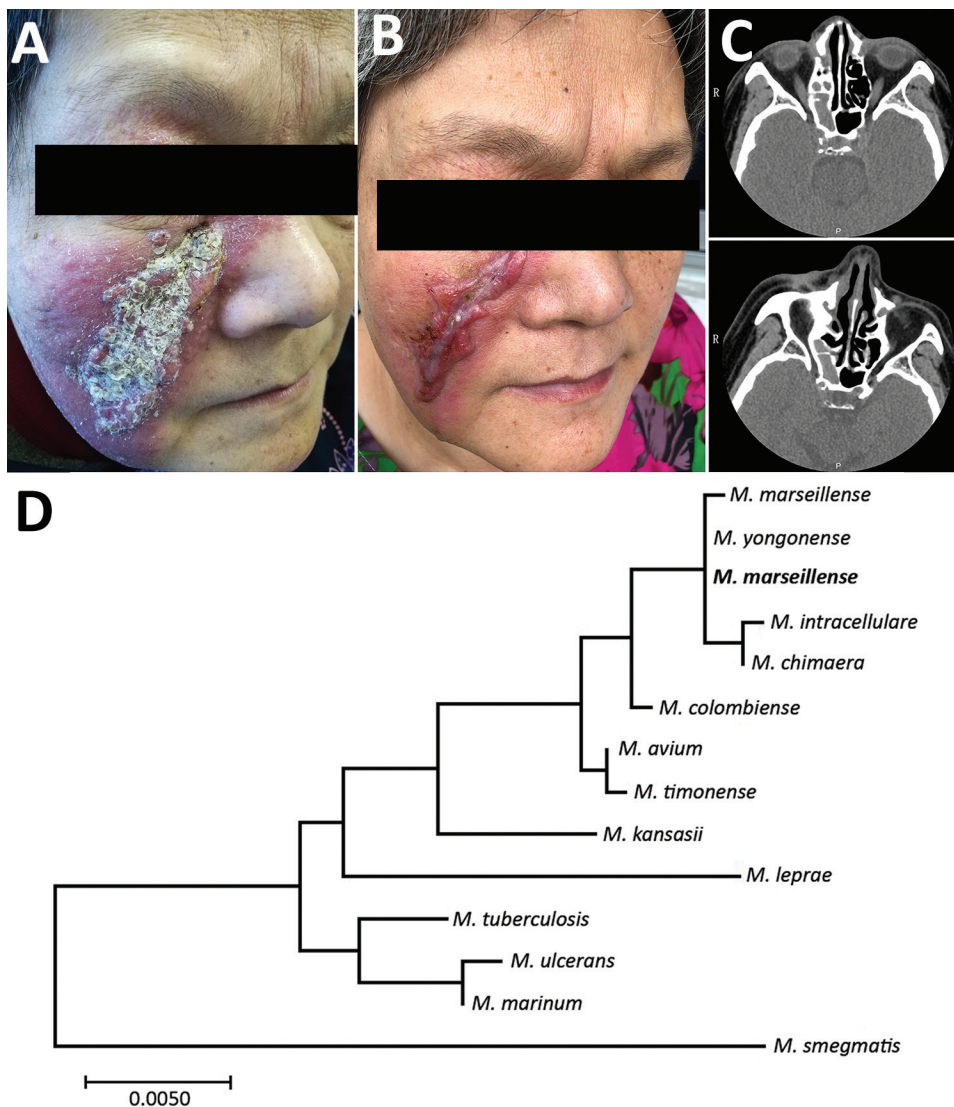


Figure. Skin lesions and computer tomography scans of woman with *Mycobacterium marseillense* skin infection, China, 2018, and genomic analysis of isolate. A, B) Facial skin lesion of woman with *M. marseillense* infection before and after treatment. Infiltrated erythematous plaque with yellowish scales and crusts (A) resolved to a scar after clearance of infection (B). C) Computed tomography imaging before treatment (top) shows heterogeneous hypersignal in right ethmoid sinus and after treatment (bottom) shows recovery of right ethmoid sinus. P, posterior; R, right. D) Phylogenetic tree constructed with 16S rRNA gene sequence of isolate from patient (bold) and other species. Scale bar indicates nucleotide substitutions per site.

remained (Figure, panel B). Computed tomography scans of the paranasal sinuses showed the reduction of sinusitis (Figure, panel C). No recurrence was observed during 4 months of monitoring.

We characterized this isolate's genome (GenBank accession no. VASI0000000) further to help determine the cause of its virulence and resistance (Appendix Figure 3). Genetic analyses indicated the genome ($\approx 5,706,022$ bp) contained 5,343 predicted genes, 3 rRNAs, and 48 tRNAs and had a GC content of 67.73%. We annotated the genes functionally through multiple databases (Appendix Table 1, Figure 4). Using the Virulence Factors of Pathogenic Bacteria database, we identified 137 potential virulence genes (identity $>95.0\%$, E value $<1 \times 10^{-5}$), such as type VII secretion system genes (e.g., *esxH*, *esxC*, *esxH*, and *esxC*) (6), in the isolate's genome (Appendix 2, <https://wwwnc.cdc.gov/EID/article/25/10/19-0695-App2.xlsx>). In Comprehensive Antibiotic Resistance Database searches,

we detected the antimicrobial drug resistance genes *mtrA*, *murA*, and *gyrA* (identity $>90.0\%$, E value $<1 \times 10^{-5}$; Appendix Table 2); *mtrA* modulates antimicrobial drug efflux, *murA* encodes the fosfomycin resistance protein, and *gyrA* encodes the fluoroquinolone resistance protein.

M. marseillense infections are rare in humans. Our case demonstrates that *M. marseillense* can cause infections in immunocompetent persons. For facial skin infection with *M. marseillense*, this and similar (7) reports indicate the need for vigilance of paranasal sinus infection. Although many potential virulence factors could be detected by genomic analysis, cases of infection and transmission with this bacterium are rarely reported, suggesting the presence of other influencing factors.

The drug resistance mechanisms of *M. marseillense* have not been completely elucidated. The drug susceptibility test results and treatment response we observed were generally consistent with those previously reported for

cases of pulmonary infection, although sensitivity to rifampin and quinolones yielded various results (2–4). Drug susceptibility testing indicated that the isolate we obtained was resistant to ethambutol and rifampin. However, in genetic analyses, mutations associated with ethambutol and rifampin resistance were not detected. According to the Comprehensive Antibiotic Resistance Database, our isolate was resistant to fluoroquinolone, but drug susceptibility test results were inconsistent. Our results indicate that drug susceptibility testing should be performed for *M. marseillense* to guide antimicrobial drug treatment. If drug susceptibility results are absent, treatments including macrolides and amikacin appear to be reasonable.

Acknowledgments

We thank Jun Chen and Ying Shi for data analysis.

This manuscript was supported by grants from the Chinese Academy of Medical Science Innovation Fund for Medical Science (2017-I2M-B&R-14, 2016-I2M-1-005), Jiangsu Provincial Science and Technology Project (BE2018619), National Science and Technology Major Project (2018ZX10101-001), Graduate Innovation Foundation of Peking Union Medical College (2018-1002-02-13), and Jiangsu Natural Science Foundation (BK20160377).

About the Author

Dr. Xie is a physician in the Department of Dermatology, Zhejiang Institute of Dermatology, Deqing, China, and formerly studied at the Institute of Dermatology, Chinese Academy of Medical Sciences and Peking Union Medical College, Nanjing, China. His major research interest is infectious diseases of the skin.

References

1. Ben Salah I, Cayrou C, Raoult D, Drancourt M. *Mycobacterium marseillense* sp. nov., *Mycobacterium timonense* sp. nov. and *Mycobacterium bouchederuhonense* sp. nov., members of the *Mycobacterium avium* complex. *Int J Syst Evol Microbiol*. 2009;59:2803–8. <https://doi.org/10.1099/ijs.0.010637-0>
2. Grottola A, Roversi P, Fabio A, Antenora F, Apice M, Tagliazucchi S, et al. Pulmonary disease caused by *Mycobacterium marseillense*, Italy. *Emerg Infect Dis*. 2014;20:1769–70. <https://doi.org/10.3201/eid2010.140309>
3. Kim SY, Yoo H, Jeong BH, Jeon K, Ha YE, Huh HJ, et al. First case of nontuberculous mycobacterial lung disease caused by *Mycobacterium marseillense* in a patient with systemic lupus erythematosus. *Diagn Microbiol Infect Dis*. 2014;79:355–7. <https://doi.org/10.1016/j.diagmicrobio.2014.03.019>
4. Azzali A, Montagnani C, Simonetti MT, Spinelli G, de Martino M, Galli L. First case of *Mycobacterium marseillense* lymphadenitis in a child. *Ital J Pediatr*. 2017;43:92. <https://doi.org/10.1186/s13052-017-0413-5>
5. Griffith DE, Aksamit T, Brown-Elliott BA, Catanzaro A, Daley C, Gordin F, et al.; American Thoracic Society Mycobacterial Diseases Subcommittee; American Thoracic Society; Infectious Disease Society of America. An official ATS/IDSA statement: diagnosis, treatment, and prevention of nontuberculous mycobacterial diseases. (Erratum in: *Am J Respir Crit Care Med* 2007;175:744–5.) *Am J Respir Crit Care Med*. 2007;175:367–416. <https://doi.org/10.1164/rccm.200604-571ST>
6. Abdallah AM, Gey van Pittius NC, DiGiuseppe Champion PA, Cox J, Luirink J, Vandenbroucke-Grauls CMJE, et al. Type VII secretion—mycobacteria show the way. *Nat Rev Microbiol*. 2007;5:883–91. <https://doi.org/10.1038/nrmicro1773>
7. Chen Y, Jiang J, Jiang H, Chen J, Wang X, Liu W, et al. *Mycobacterium gordonae* in patient with facial ulcers, nosebleeds, and positive T-SPOT.TB test, China. *Emerg Infect Dis*. 2017;23:1204–6. <https://doi.org/10.3201/eid2307.162033>

Address for correspondence: Hongsheng Wang, Chinese Academy of Medical Sciences and Peking Union Medical College, Institute of Dermatology, St 12 Jiangwangmiao, Nanjing, Jiangsu, 210042, China; email: whs33@vip.sina.com

Geospatial Variation in Rotavirus Vaccination in Infants, United States, 2010–2017

Mary A.M. Rogers, Catherine Kim, Annika M. Hofstetter

Author affiliations: University of Michigan, Ann Arbor, Michigan, USA (M.A.M. Rogers, C. Kim); University of Washington and Seattle Children's Research Institute, Seattle, Washington, USA (A.M. Hofstetter)

DOI: <https://doi.org/10.3201/eid2510.190874>

We evaluated rotavirus vaccination rates in the United States by using records from a nationwide health database. From data on 519,697 infants, we found 68.6% received the entire rotavirus vaccine series. We noted pockets of under-vaccination in many states, particularly in the Northeast and in some western states.

Vaccination coverage in the United States frequently is evaluated with telephone and mailed surveys (1). However, telephone response rates have declined over the past 2 decades (2) and parents who choose not to vaccinate their children might be less likely to participate in surveys (3).

Mycobacterium marseillense Infection in Human Skin, China, 2018

Appendix 1

Material and Methods

Ethic Statement

Informed consent was obtained from the patient. Ethics approval was obtained from the ethics review board of the Institute of Dermatology, Chinese Academy of Medical Sciences, Nanjing, China.

Tissue Culture, Bacterial Strains, Genomic DNA Extraction and Sequencing

Skin tissue grinding fluid and nasal discharge from the patient were collected and cultured on Löwenstein–Jensen medium at 32°C and 37°C. The grown colonies of bacteria on Löwenstein–Jensen medium were then carefully transferred to Middlebrook 7H10 agar with Middlebrook oleic albumin dextrose catalase (OADC) enrichment and cultured at 37°C.

Mycobacterium marseillense used in our study was isolated from the skin tissue of our patient. Genomic DNA Isolation was performed using a DNeasy Blood & Tissue kit (QIAGEN, The Netherlands) according to the manufacturer's instructions. The DNA purity and concentration was measured by NanoDrop 2000 spectrophotometer. Genome sequencing was conducted by Novogene Technology Co. Ltd (Beijing, China) using Illumina PE150.

Genome Analyses

Circular genome maps were generated using Circos (Version 0.64) based on analysis of the coverage of sample sequencing reads, single-nucleotide polymorphisms (SNPs), and InDels. The coding genes were predicted by GeneMarkS software. CRISPRdigger was used to predict the CRISPRs (clustered regularly interspaced short palindromic repeats) of the genome. Scattered repeat sequences were predicted by RepeatMasker software, and TRF searched for tandem repeats in DNA sequences. Functional annotations were performed using the non-redundant protein (Nr) database, SwissProt, the Kyoto Encyclopedia of Genes and Genomes (KEGG) database, Cluster of Orthologous Groups of proteins (COG), Gene Ontology (GO), and protein families (Pfam). Antimicrobial resistance genes were detected based on the Antibiotic Resistance Genes Database (ARDB) and Comprehensive Antibiotic Resistance Database (CARD). Virulence factor annotation was carried out based on Virulence Factors of Pathogenic Bacteria database (VFDB) and Pathogen-Host Interactions database (PHI).

Phylogenetic Analyses

The phylogenetic tree was built based on the 16S rRNA gene sequence of *M. marseillense* in this study and other reference strains, including *Mycobacterium intracellulare* ATCC 13950, *Mycobacterium avium* subsp. paratuberculosis K-10, *Mycobacterium chimaera* strain AH16, *Mycobacterium marseillense* strain FLAC0026, *Mycobacterium colombiense* CECT 3035, *Mycobacterium intracellulare* subsp. *yongonense* 05–1390, *Mycobacterium timonense* CCUG 56329, *Mycobacterium kansasii* ATCC 12478, *Mycobacterium leprae* TN, *Mycobacterium tuberculosis* H37Rv, *Mycobacterium ulcerans* Agy99, *Mycobacterium marinum* E11, and *Mycobacterium smegmatis* strain MC2 155. The gene sequences were downloaded from the NCBI.

Appendix Table 1. Information on *Mycobacterium marseillense**

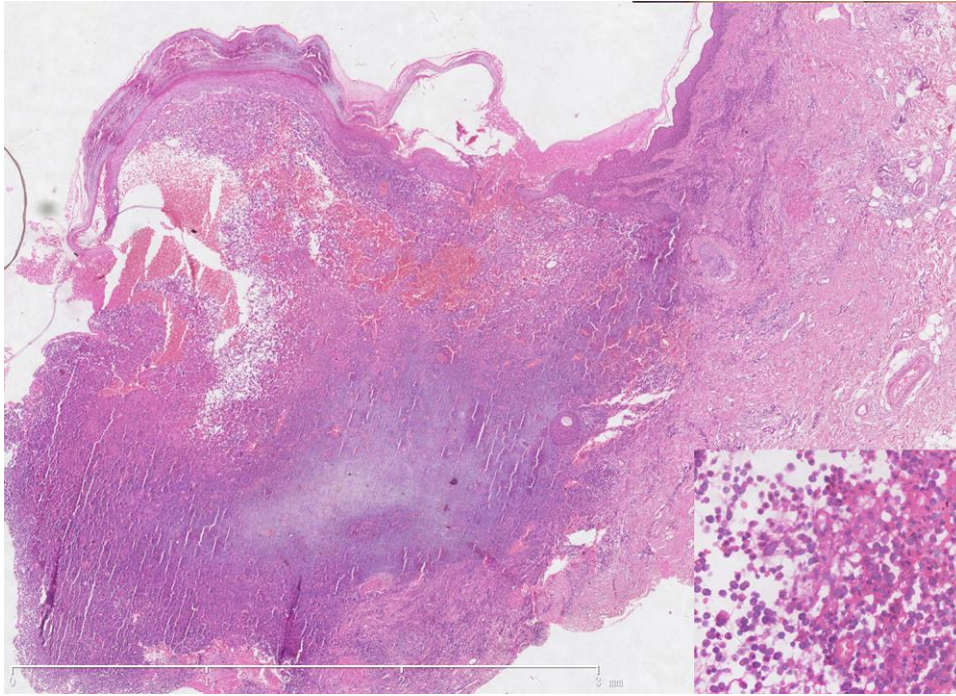
Sample ID	nr	SwissProt	KEGG	COG	TCDB	GO	PHI	VFDB	ARDB	CARD	Secretory protein	T3SS	CAZY
<i>M. marseillense</i>	5,220	2,309	5,164	3,836	295	3,467	292	454	0	27	108	186	140

*ARDB, Antibiotic Resistance Genes Database; CARD, Comprehensive Antibiotic Resistance Database; CAZY, Carbohydrate-Active enZymes Database; COG, Cluster of Orthologous Group; GO, Gene Ontology; ID, identification; KEGG, Kyoto Encyclopedia of Genes and Genomes; NR, redundant protein database; PHI, Pathogen-Host Interactions database; T3SS, type 3 secretion system; TCDB, Transporter Classification Database; VFDB, Virulence Factors of Pathogenic Bacteria database.

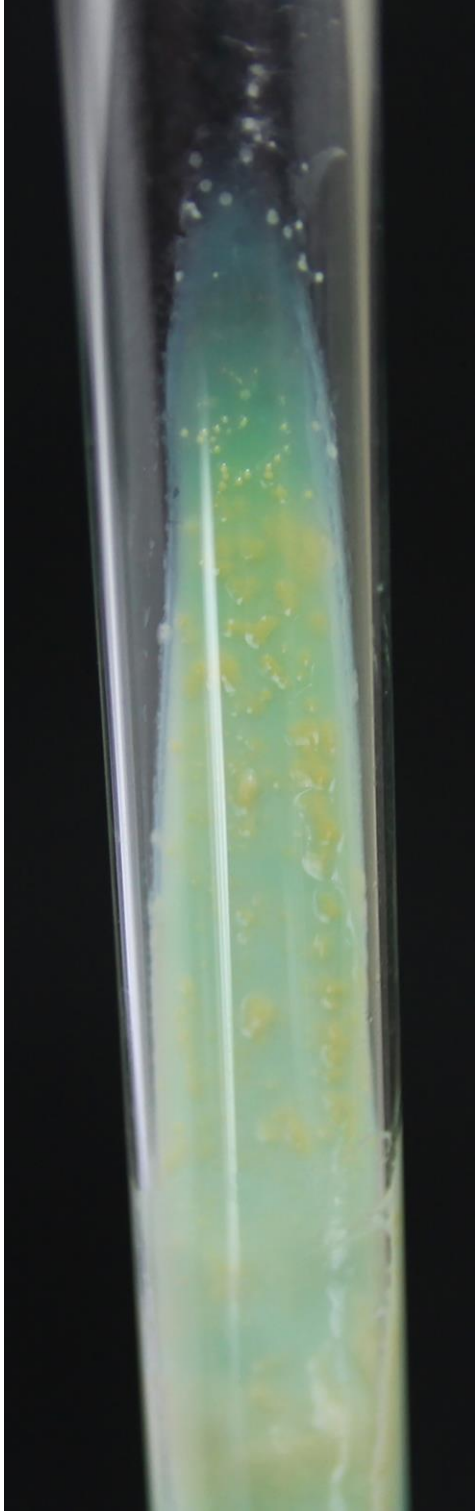
Appendix Table 2. Antimicrobial resistance genes found in *Mycobacterium marseillense* isolate from patient, China, 2018*

ORF ID	Best Hit e		Best			Bit	
	value	Best Hit ARO	Identities	ARO	ARO name	score	ARO category
<i>M. marsei</i> GM004178, locus = Scaffold 16: 52255:52917:-	2.35E-157	mtrA	1	ARO: 3000816	mtrA	436.032	efflux pump conferring antibiotic resistance, gene modulating antibiotic efflux
<i>M. marsei</i> GM003653, locus = Scaffold 12: 152238:153491:+	0	Mycobacterium tuberculosis murA	0.96875	ARO: 3003784	Mycobacterium tuberculosis murA	813.142	fosfomycin resistance protein
<i>M. marsei</i> GM000974, locus = Scaffold 3: 140161:142677:+	0	Mycobacterium tuberculosis gyrA conferring resistance to fluoroquinolones	0.932934	ARO: 3003295, ARO: 3003941	Mycobacterium tuberculosis gyrA conferring resistance to fluoroquinolones, Shigella flexneri parC conferring resistance to fluoroquinolones	1572.76, 386.726	antibiotic resistant gene variant or mutant, fluoroquinolone resistance protein

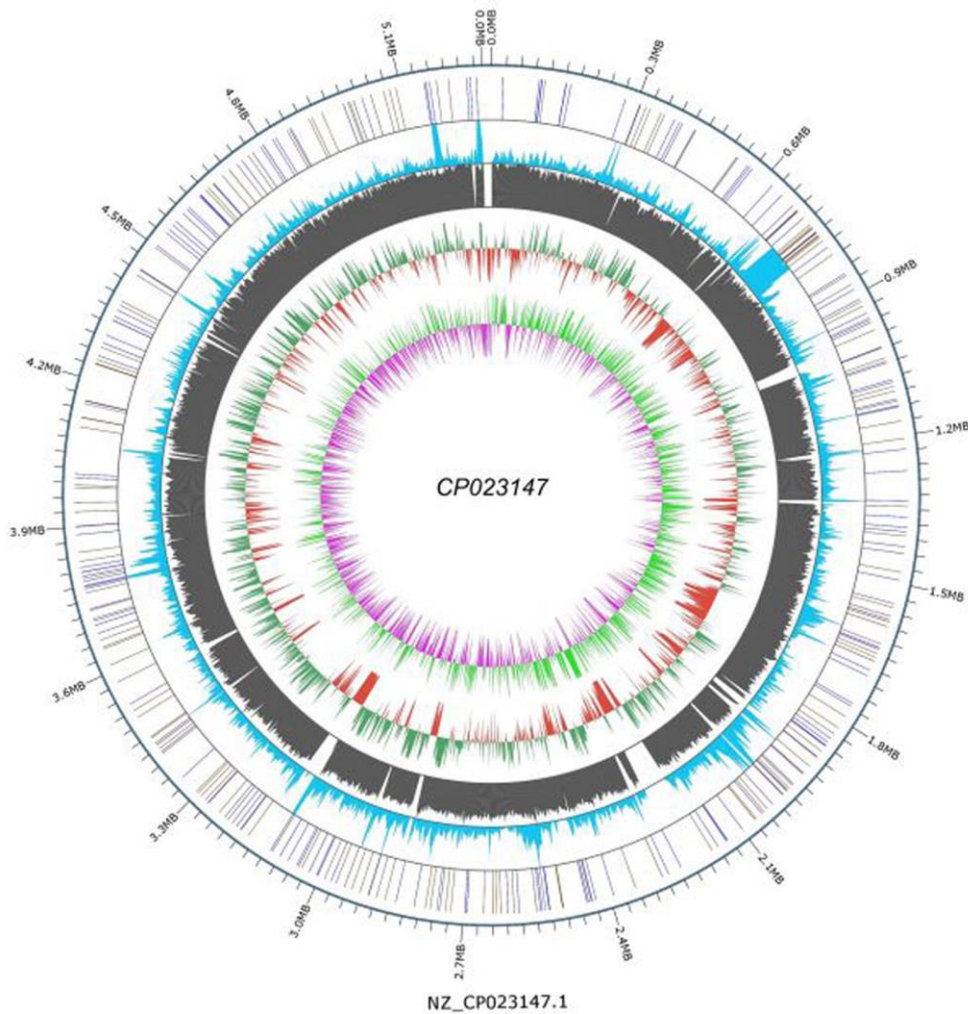
*ARO, antibiotic resistance ontology; ID, identification; ORF, open reading frame.



Appendix Figure 1. Hematoxylin and eosin stain of skin lesion (original magnification $\times 4$). Inset shows part of the sample.

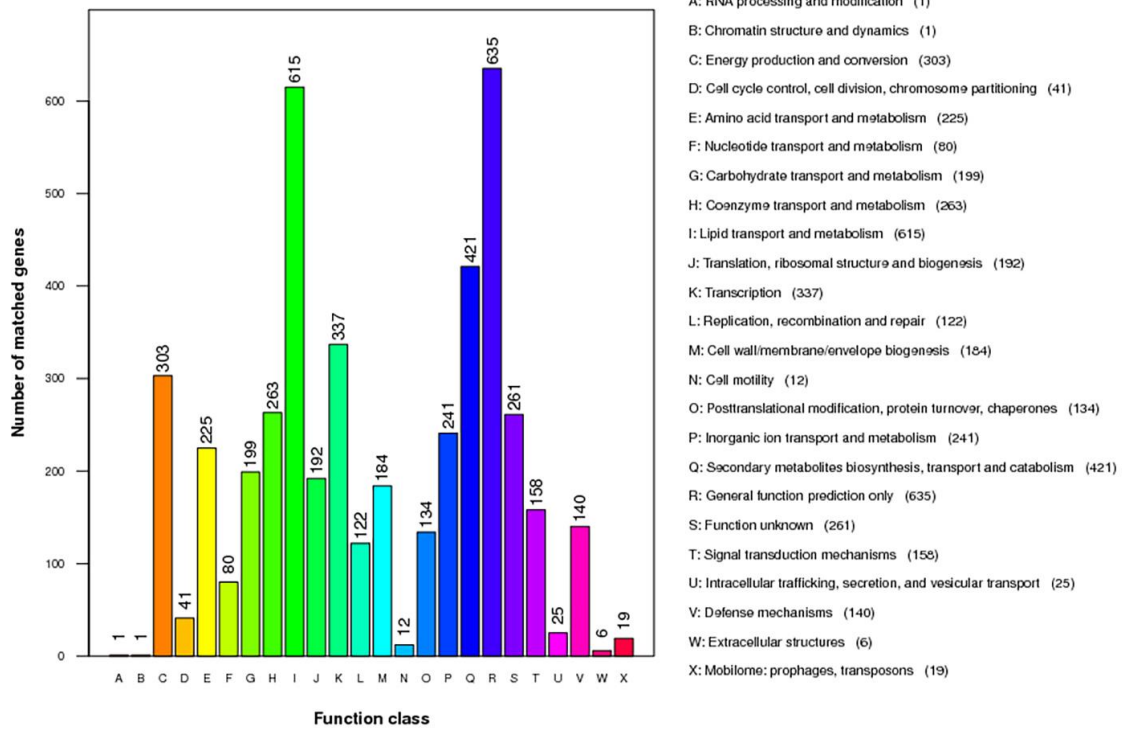


Appendix Figure 2. Tissue homogenate culture showing bacterial colonies after incubation on Löwenstein–Jensen medium.



Appendix Figure 3. Overview of *Mycobacterium marseillense* genome. From the outermost to the innermost circle: the position coordinate of the reference sequence, the InDel distribution of the sample, the single-nucleotide polymorphism (SNP) number distribution of the sample, the reads coverage depth of the sample, the GC content of the reference sequence genome, and the GC skew value distribution of the reference sequence genome, respectively.

COG function classification



Appendix Figure 4. Function categories of genes by Cluster of Orthologous Group annotation.