

for persons with cryptococcal meningitis but without bacteremia was 30% (47/158); 1 patient was lost to follow-up. Thus, the estimated attributable mortality rate for bacteremia was 13% (odds ratio 1.8, 95% CI 0.78–4.0, $p = 0.17$) compared with patients without bacteremia during their initial hospitalization.

Case-control comparisons identified no risk factors for bacteremia (online Technical Appendix, [wwwnc.cdc.gov/EID/article/20/4/13-1277-Techapp1.pdf](http://www.cdc.gov/EID/article/20/4/13-1277-Techapp1.pdf)). Although 21 (70%) of 30 bacteremia episodes were preceded by phlebitis at a peripheral intravenous site, phlebitis caused by amphotericin was also common in patients without bacteremia (49%), but these percentages did not differ statistically.

Accurate data regarding incidence of nosocomial infections in Africa are lacking. A systematic review by WHO in 2011 that assessed published data for 1995–2009 identified only 2 high-quality studies. WHO estimated a prevalence of 2.5%–14.8% for nosocomial infections and a cumulative incidence of up to 45.8% in some areas (4) and recommended surveillance to estimate the rates of nosocomial infection. WHO acknowledges that health care-associated infections are causes of prolonged hospitalizations, increased antimicrobial drug resistance, financial burdens on health care systems, and causes of excess illness and death (5).

Limitations of our study include the retrospective design and inability to identify predictive risk factors for bacteremia. Given the differences in bacteremia incidence between our 2 sites, findings are probably not generalizable to all clinical settings in Africa. However, these findings identify a clinical problem.

The incidence of nosocomial bacteremia was 15% in our hospitalized cryptococcal meningitis cohort at a median time of 14 days after hospitalization. The most frequent etiologies were *S. aureus* and *K. pneumoniae*. Less than 25%

of isolates were sensitive to ceftriaxone, a standard empiric drug used throughout Africa. Further prospective studies are needed to determine the prevalence and risk factors for nosocomial infections and prevalence of multidrug resistance among hospitalized persons in resource-limited areas.

This study was supported by the National Institute of Allergy and Infectious Diseases, National Institutes of Health (grants U01AI089244 and K23AI073192). G.M. (grant 098316) and J.S. (grant 081667) were supported by the Wellcome Trust.

**Radha Rajasingham,
Darlisha Williams,
David B. Meya,
Graeme Meintjes,
David R. Boulware,
and James Scriven**

Author affiliations: University of Minnesota, Minneapolis, Minnesota, USA (R. Rajasingham, D. Williams, D.B. Meya, D.R. Boulware); Makerere University, Kampala, Uganda (D. Williams, D.B. Meya); University of Cape Town, Cape Town, South Africa (G. Meintjes, J. Scriven); Imperial College London, London, UK (G. Meintjes); and Liverpool School of Tropical Medicine, Liverpool, UK (J. Scriven)

DOI: <http://dx.doi.org/10.3201/eid2004.131277>

References

- Allegranzi B, Nejad SB, Combescure C, Graafmans W, Attar H, Donaldson L, et al. Burden of endemic health-care-associated infection in developing countries: systematic review and meta-analysis. *Lancet*. 2011;377:228–41. [http://dx.doi.org/10.1016/S0140-6736\(10\)61458-4](http://dx.doi.org/10.1016/S0140-6736(10)61458-4)
- Paterson DL, Ko W-C, Gottberg Von A, Mohapatra S, Casellas JM, Goossens H, et al. International prospective study of *Klebsiella pneumoniae* bacteremia: implications of extended-spectrum beta-lactamase production in nosocomial infections. *Ann Intern Med*. 2004;140:26–32. <http://dx.doi.org/10.7326/0003-4819-140-1-200401060-00008>
- World Health Organization. Rapid advice: diagnosis, prevention and management of cryptococcal disease in HIV-infected adults, adolescents, 2011 [cited 2014 Jan 7]. www.who.int/hiv/pub/cryptococcal_disease2011/en/
- Bagheri Nejad S, Allegranzi BB, Syed SBS, Ellis BB, Pittet DD. Health-care-associated infection in Africa: a systematic review. *Bull World Health Organ*. 2011;89:757–65. <http://dx.doi.org/10.2471/BLT.11.088179>
- World Health Organization. Report on the burden of endemic health care-associated infection worldwide, 2011 [cited 2014 Jan 7]. http://whqlibdoc.who.int/publications/2011/9789241501507_eng.pdf

Address for correspondence: Radha Rajasingham, Beth Israel Deaconess Medical Center, Harvard Medical School, 110 Francis St, Ste GB, Boston, MA 02215, USA; email: radha.rajasingham@gmail.com

Severe Babesiosis in Immunocompetent Man, Spain, 2011

To the Editor: Babesiosis, a malaria-like illness, is transmitted through *Ixodes* ticks by the zoonotic parasites, *Babesia* spp. In humans, these parasites are transferred from mammalian animal reservoirs, and the rate of infection in humans is increasing. Babesiosis also potentially threatens the blood supply because asymptomatic infections in humans are common; such infections can be life-threatening in some recipients (1). Most human infection is caused by *B. microti*, but babesiosis caused by *B. divergens*, *B. duncani*, and *B. venatorum* has been reported.

Human babesiosis can be clinically silent or progress to a fulminant malaria-like disease. The infection resolves spontaneously or after treatment with azithromycin/atovaquone or clindamycin/quinine. However, immunocompromised patients may respond suboptimally to these drug regimens (2). Given the death rate

associated with babesiosis, no treatment is fully satisfactory (3). Infection with *B. divergens* is particularly problematic and is associated with a high death rate in splenectomized or immunocompromised patients (3). In Europe, sporadic cases of babesiosis have also been reported in immunocompetent persons (4).

In October 2011, a 46-year-old man whose spleen was intact was hospitalized after 3 days of fever, severe abdominal pain, jaundice, and black and red deposits in his urine. The man lived in a rural area in Asturias, Spain, where he was employed as a forest ranger. He reported that he removed ticks from his dogs.

Laboratory findings included hemoglobin 12.3 g/dL (reference range 13.8–17.2 g/dL); creatinine 1.52 mg/dL (reference range 0.7–1.3 mg/dL); total and direct/conjugated bilirubin 18.4 and 12.8 mg/dL (reference ranges total 0.3–1.9 mg/dL; direct/conjugated 0–0.3 mg/dL), lactate dehydrogenase 822 IU/L (reference range 105–333 IU/L); and showed thrombopenia, low haptoglobina, and hematuria. A value of 35% CD4+ T cells (reference range 30%–60%) indicated normal immune status. Results of serologic tests for hepatitis; HIV; and *Bartonella*, *Brucella*, *Leishmania*, *Leptospira*, and *Borrelia* spp. and of blood cultures were negative. Abdominal ultrasound scan revealed mild hepatomegaly and cortical echogenicity compatible with acute kidney failure. Howell-Jolly bodies were identified in blood, and functional splenic studies were conducted. Scintigraphic parameters showed a normal deposit of radioactive hepato-splenic material, compatible with a normal-sized spleen of 13.4 cm.

Giemsa-stained blood smears showed intra-erythrocytic parasites, mainly observed in the 2-celled dividing pyriform stage, leading to the diagnosis of babesiosis with a parasitemia level of 10% (Figure). The complete *B. divergens* 18S rRNA gene was amplified

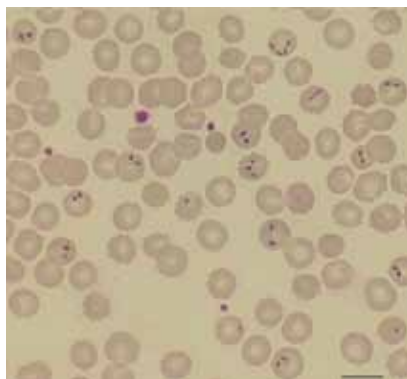


Figure. A Giemsa-stained thin film of blood from a 46-year-old man showing *Babesia divergens*. Double pear shaped intraerythrocytic parasites are indicated by arrows. Slides were examined with a Nikon microscope (Nikon Instruments, Inc., Melville, NY, USA) at 60 \times magnification. Scale bar indicates 500 nm. A color version of this figure is available online (wwwnc.cdc.gov/eid/article/20/4/13-1409-F1.htm).

from the patient's blood (5), and the nucleotide sequencing (GenBank accession no. KF533077) showed 100% homology with *B. divergens* human strains (GenBank accession nos. FJ944822 and FJ944823) (5) and with 2 babesiosis cases reported previously (4). Indirect immunofluorescent assays of *B. divergens* cultures showed specific antibodies against *B. divergens* in the patient's serum (online Technical Appendix Figure, wwwnc.cdc.gov/EID/article/20/4/13-1409-Techapp1.pdf). The patient was treated with 650 mg oral quinine every 8 hours and 600 mg intravenous clindamycin every 6 hours. The parasitemia diminished gradually and resolved 10 days later, but the hemolytic anemia remained severe, as evidenced by hemoglobin of 7.2 g/dL.

The man's illness unexpectedly relapsed on day 18 after treatment. His reticulocyte count was elevated, and parasites were once again detected in blood samples. Thus, treatment was changed to a combination of atovaquone/proguanil 250/100 mg administered every 8 hours plus azithromycin 500 mg every 24 hours. Two weeks later, the patient's hemoglobin was 8.7

g/dL, and no parasites were detectable by microscopy. The treatment was extended for an additional 5 weeks, and the patient was free of parasites on subsequent visits.

We have described what appears to be the third case of human babesiosis in nonsplenectomized patients in Europe. Human presence in tick, cattle, and domestic animal habitats could be responsible for this case. Martinot et al. (4) earlier pointed out that in Europe, babesiosis can also occur in persons with intact spleens. A combination of clindamycin and quinine is the recommended treatment of severe babesiosis (2,3). However, in this case, the recommended therapy failed, and therapy was switched to atovaquone/proguanil plus azithromycin. Other case reports have also related failure, ineffectiveness, adverse reaction, or persistent and relapsing babesiosis to clindamycin and quinine treatment in splenectomized patients infected by *B. divergens* or *B. microti* (3,6–9) or suspected *B. microti* drug resistance in immunocompromised patients (2). The recently sequenced *B. microti* genome reveals absence of proteases necessary to digest host hemoglobin and hemozoin formation by the parasite; this absence may explain the ineffectiveness of chloroquine, and perhaps other compounds of the aminoquinoline family used in babesiosis therapy (10).

This clinical case report, together with the failure of clindamycin and quinine to successfully eliminate the parasite *Babesia*, again opens the debate about the limitations of conventional treatment for severe human babesiosis in immunocompetent and immunocompromised patients. The capability of *Babesia* spp. to invade erythrocytes is the key step of the disease process. Focusing on *Babesia* spp. molecules involved in the invasion steps may offer new targets for the development of new prophylaxis and treatment for human babesiosis.

Acknowledgments

We thank Aurelio Velasco for reviewing the manuscript.

This work was funded by grants from Ministerio de Economía y Competitividad (AGL2010-21774) and Instituto de Salud Carlos III (MPY1411/09) from Spain to E.M. Work in the laboratory of C.A.L. is funded by the NIH (HL105694).

Luis M. Gonzalez, Susana Rojo, Fernando Gonzalez-Camacho, Daniel Luque, Cheryl A. Lobo, and Estrella Montero

Author affiliations: Centro Nacional de Microbiología, Majadahonda, Spain (L.-M. Gonzalez, F. Gonzalez-Camacho, D. Luque, E. Montero), Hospital Universitario Central de Asturias, Asturias, Spain (S. Rojo); and New York Blood Center, New York, New York, USA (C.A. Lobo)

DOI: <http://dx.doi.org/10.3201/eid2004.131409>

References

1. Lobo CA, Cursino-Santos JR, Alhassan A, Rodrigues M. *Babesia*: an emerging infectious threat in transfusion medicine. *PLoS Pathog*. 2013;9:e1003387. <http://dx.doi.org/10.1371/journal.ppat.1003387>
2. Wormser GP, Prasad A, Neuhaus E, Joshi S, Nowakowski J, Nelson J, et al. Emergence of resistance to azithromycin-atovaquone in immunocompromised patients with *Babesia microti* infection. *Clin Infect Dis*. 2010;50:381–6.
3. Gorenflot A, Moubri K, Precigout E, Carcy B, Schetters TP. Human babesiosis. *Ann Trop Med Parasitol*. 1998;92:489–501. <http://dx.doi.org/10.1080/00034989859465>
4. Martinot M, Zadeh MM, Hansmann Y, Grawey I, Christmann D, Aguilon S, et al. Babesiosis in immunocompetent patients, Europe. *Emerg Infect Dis*. 2011;17:114–6. <http://dx.doi.org/10.3201/eid1701.100737>
5. Malandrin L, Jouglin M, Sun Y, Brisseau N, Chauvin A. Redescription of *Babesia capreoli* (Enigk and Friedhoff, 1962) from roe deer (*Capreolus capreolus*): isolation, cultivation, host specificity, molecular characterisation and differentiation from *Babesia divergens*. *Int J Parasitol*. 2010;40:277–84. <http://dx.doi.org/10.1016/j.ijpara.2009.08.008>
6. Centeno-Lima S, do Rosario V, Parreira R, Maia AJ, Freudenthal AM, Nijhof AM, et al. A fatal case of human babesiosis in Portugal: molecular and phylogenetic analysis. *Trop Med Int Health*. 2003;8:760–4. <http://dx.doi.org/10.1046/j.1365-3156.2003.01074.x>
7. Corpelet C, Vacher P, Coudore F, Laurichesse H, Conort N, Souweine B. Role of quinine in life-threatening *Babesia divergens* infection successfully treated with clindamycin. *Eur J Clin Microbiol Infect Dis*. 2005;24:74–5. <http://dx.doi.org/10.1007/s10096-004-1270-x>
8. Haapasalo K, Suomalainen P, Sukura A, Siikamaki H, Jokiranta TS. Fatal babesiosis in man, Finland, 2004. *Emerg Infect Dis*. 2010;16:1116–8. <http://dx.doi.org/10.3201/eid1607.091905>
9. Hatcher JC, Greenberg PD, Antique J, Jimenez-Lucho VE. Severe babesiosis in Long Island: review of 34 cases and their complications. *Clin Infect Dis*. 2001;32:1117–25. <http://dx.doi.org/10.1086/319742>
10. Cornillot E, Hadj-Kaddour K, Dassouli A, Noel B, Ranwez V, Vacherie B, et al. Sequencing of the smallest Apicomplexan genome from the human pathogen *Babesia microti*. *Nucleic Acids Res*. 2012;40:9102–14. <http://dx.doi.org/10.1093/nar/gks700>

Address for correspondence: Estrella Montero, Centro Nacional de Microbiología, Instituto de Salud Carlos III, Carretera Majadahonda-Pozuelo, Km 2,2, Majadahonda, Madrid, 28220, Spain; email: estrella.montero@isciii.es

Q Fever Endocarditis and New *Coxiella burnetii* Genotype, Saudi Arabia

To the Editor. Q fever is a worldwide zoonosis caused by an obligate intracellular bacterium, *Coxiella burnetii* (1). Q fever endocarditis is associated with surgery for 15%–73% of patients, causes death for 5%–65% of patients, and induces a large number of relapses when the endocarditis is inadequately treated (1). The most serious risk factor for endocarditis is a substantial underlying valvulopathy, but progression to endocarditis is

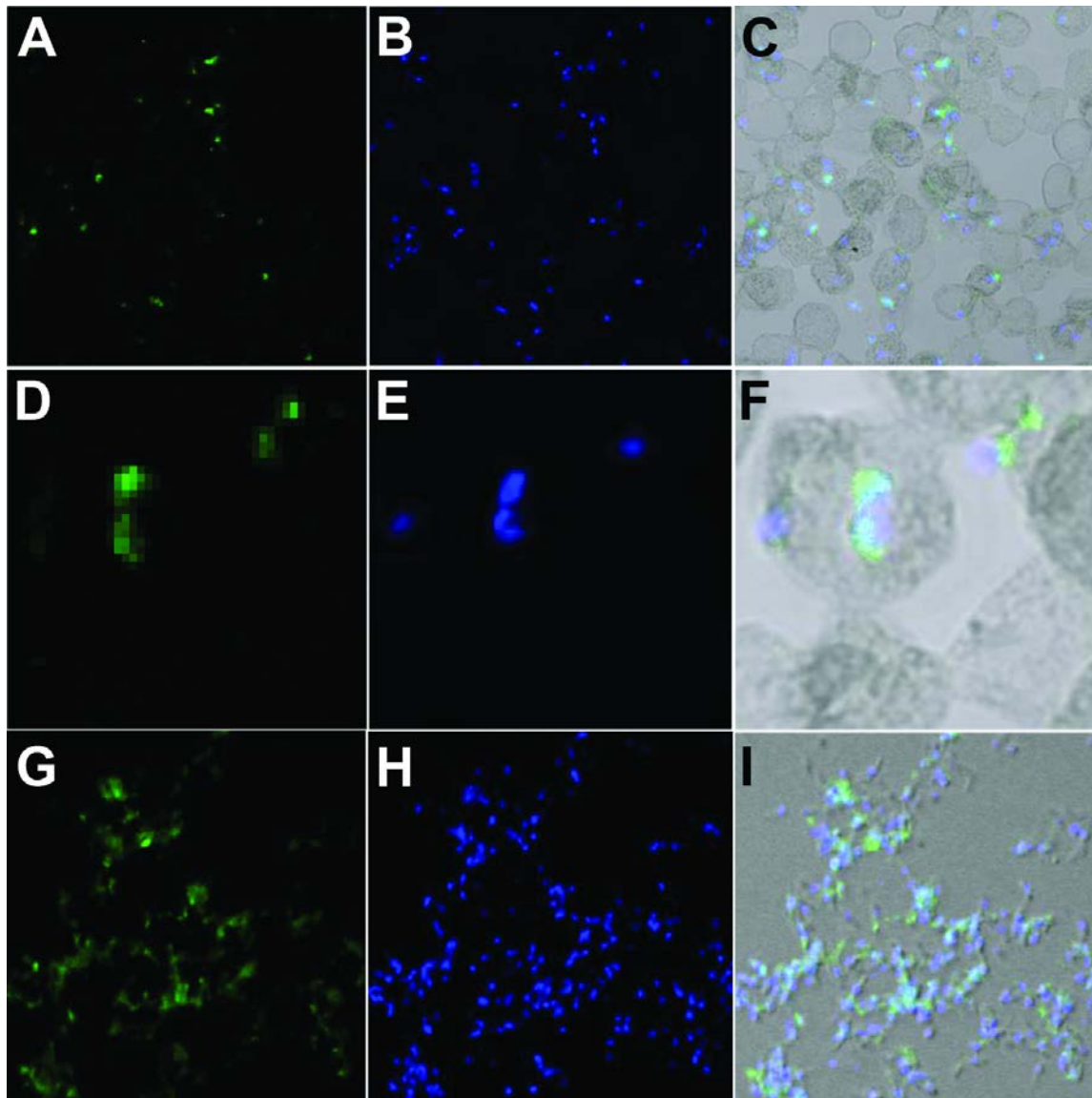
also found in patients with clinically silent, previously undiagnosed, valvulopathies (1). Since the 1960s, Q fever has been recognized as a public health problem in Saudi Arabia, and studies have shown that coxiellosis occurs in livestock (2,3). Only a few cases of Q fever endocarditis in Saudi Arabia have been reported (4–6). We report 2 new cases of Q fever endocarditis and detection of a new *C. burnetii* genotype in this country.

The first case was detected in 2007 in a 45-year-old man in Saudi Arabia who had fever, pneumonia, and asthenia. A transesophageal echocardiogram showed endocarditis. Results of an immunofluorescence assay were positive for *C. burnetii*; phase I titers for IgG, IgM, and IgA were 51,200, 100, and 25, respectively, and phase II titers were 102,400, 200, and 50, respectively. Serum and blood samples were negative for *C. burnetii* by real-time PCR for the IS1111 and the IS30A spacers (7). For each sample, the quality of DNA extraction was verified by real-time PCR for a housekeeping gene encoding β -actin (7). The aortic valve was surgically replaced, and *C. burnetii*-specific PCR results for the valve were positive. According to multispacer sequence typing (8), this *C. burnetii* isolate was a new genotype, MST51 (Figure). A *C. burnetii* isolate was cultured from the valve of this patient by the shell-vial method that used human embryonic lung cells (7). IgG anticardiolipin testing results were negative (9). The patient was given 200 mg oral doxycycline daily and 200 mg oral hydroxychloroquine 3 times daily for 18 months.

The second case was detected in 2012 in a 13-year-old boy in Saudi Arabia who had tetralogy of Fallot, a prosthetic pulmonary valve, 2 intracardiac stents, and long-term fever. Serologic testing results were positive for *C. burnetii*; phase I titers for IgG, IgM, and IgA were 51,200, 400, and 200, respectively, and phase II titers were 102,400, 800, and 400, respectively. Whereas serum and blood

Severe Babesiosis in Immunocompetent Man, Spain, 2011

Technical Appendix



Technical Appendix Figure. Immunofluorescent assays of intra-erythrocytic and free parasites were performed by using antibodies and *Babesia divergens* smears of a 46-year-old man that were prepared from in vitro human erythrocyte cultures (Bd Rouen 1986 strain). Bound antibody was detected by using fluorescein isothiocyanate-conjugated anti-human IgG. The preparations were counterstained with DAPI and examined by confocal microscopy. Samples were laser-stimulated at 488 and 405 nm. Intraerythrocytic parasites probed with patient IgG are shown in panels A and B and isolated free extracellular merozoites in panel C. Panels D, E, and F show the DNA of these same parasites stained with DAPI. Panels G, H, and I show both images overlaid. The immunofluorescent assays, using serum from healthy volunteers, were negative (data not shown).