

Clinical Findings for Early Human Cases of Influenza A(H7N9) Virus Infection, Shanghai, China

Shuihua Lu,¹ Yufang Zheng,¹ Tao Li,¹ Yunwen Hu,¹ Xinian Liu, Xiuhong Xi, Qingguo Chen, Qingle Wang, Ye Cao, Yanbing Wang, Lijun Zhou, Douglas Lowrie, and Jing Bao

A novel strain of influenza A(H7N9) virus has emerged in China and is causing mild to severe clinical symptoms in infected humans. Some case-patients have died. To further knowledge of this virus, we report the characteristics and clinical histories of 4 early case-patients.

Aavian influenza A(H7N9) virus normally circulates among birds; however, human infections with this virus were confirmed in China on March 31, 2013 (1,2). To help identify the best treatment strategies for influenza A(H7N9) virus infection, we summarized the clinical characteristics and outcomes for the first 4 patients who were transferred to Shanghai Public Health Clinical Center (SHPHCC) for treatment of influenza A(H7N9) virus infection. For each case, infection was confirmed by the Shanghai Municipal Centers for Disease Control and Prevention.

Case Reports

Clinical features of the 4 case-patients are listed in Table 1. All case-patients were 58- to 73-year-old married men, farmers or retirees, and long-term residents of Shanghai (Fengxian, Baoshan, Songjiang, and Pudong districts, respectively). Case-patient 1 had a history of coronary heart disease and hepatic schistosomiasis; case-patient 2 had no history of chronic disease; case-patient 3 had a history of hypertension and gout; and case-patient 4 had a

history of hypertension and repetitive cough for >10 years during spring and autumn.

Case-patient 1 raised chickens at home. Case-patients 2–4 had no clear history of close contact with poultry; however, each had visited various farmers' markets that sold live poultry. None of the patients raised pigeons or live in or near a heavily pigeon-infested area.

Before being transferred to SHPHCC on April 6, 2013 (patients 1 and 2) and April 7, 2013 (patients 3 and 4), the 4 patients had been treated in local hospitals; infection with influenza A(H7N9) virus had been confirmed by real-time reverse transcription PCR of nasopharyngeal swab samples before transfer. The case-patients had cough and fever and had been expectorating sputum for ≈6–7 days before admittance to SHPHCC. In addition, all had experienced cold-like symptoms and fatigue before influenza-like symptoms developed. Case-patient 4 had cough and fever for 18 and 10 days, respectively, before being transferred to SHPHCC; his case was the most serious of the 4, and the disease progressed rapidly after he was transferred to SHPHCC.

Total leukocyte counts for case-patients 1–4 were within or slightly below reference values: 5.50, 5.95, 3.50, and $4.60 \times 10^9/L$, respectively (reference value $4.00\text{--}10.00 \times 10^9/L$). The proportions of neutrophils were normal or slightly high: 79.6%, 62.6%, 72.4%, and 68.0%, respectively (reference value 50.0%–70.0%). Laboratory test results at admission are shown in Table 2. Radiograph findings mainly included ground-glass opacity and consolidation (Figures 1, 2; online Technical Appendix Figures 1, 2, wwwnc.cdc.gov/EID/article/19/7/13-0612-Techapp1.pdf). Computed tomography (CT) scans and radiograph findings, along with clinical manifestations and laboratory test results, helped establish early diagnoses.

To ensure proper treatment/management of the patients, an emergency team was established; the team followed the procedures shown in online Technical Appendix Figure 3. All 4 case-patients were administered antimicrobial drugs and the antiviral drug oseltamivir. Case-patient 1 began treatment 6 days after the onset of hypoxia, when large areas of lung inflammation were seen on radiographs. Case-patient 2 was treated 4 days after the onset of fever, when CT scan results revealed inflammation in the left upper lung lobe. Case-patient 3 began treatment 4 days after the onset of cough, sputum, and shortness of breath and after CT scan results revealed inflammation in the left lower lung lobe. Case-patient 4 began treatment 16 days after onset of high fever, dyspnea on exertion, and hypoxemia. Additional details for each patient are included below, and results of viral testing done at admission and 5 days later are shown in online Technical Appendix Table 1. Disease characteristics for infections caused by influenza virus

Author affiliations: Shanghai Public Health Clinical Center, Shanghai, China (S. Lu, Y. Zheng, T. Li, Y. Hu, X. Liu, X. Xi, Q. Chen, Q. Wang, Y. Cao, Y. Wang, L. Zhou, D. Lowrie); and Henry M Jackson Foundation—Division of AIDS, National Institute of Allergy and Infectious Diseases, National Institutes of Health, Bethesda, MD, USA (J. Bao)

DOI: <http://dx.doi.org/10.3201/eid1907.130612>

¹These authors contributed equally to this article.

subtypes H1N1, H5N1, and H7N9 are shown in online Technical Appendix Table 2.

Case-patient 1 was receiving noninvasive ventilator-assisted breathing when he arrived at SHPHCC. His oxygen saturation remained at $\approx 95\%$, and he was given continuous intravenous dopamine infusion. He had acute respiratory failure, coronary heart disease (stage 2 heart failure), and renal function insufficiency at admission. On April 11, 11

days after the onset of the symptoms and 2 hours after endotracheal intubation and mechanical ventilation began, he died from respiratory failure.

Case-patient 2 arrived at SHPHCC with a nasal cannula inserted to maintain oxygen saturation at 95%. His general condition improved steadily after commencing antiviral drug treatment, and he was discharged 18 days after illness onset.

Table 1. Clinical characteristics and treatment outcomes for 4 patients with early cases of influenza A(H7N9) virus infection, Shanghai, China*

Characteristic/treatment	Case-patient no.			
	1	2	3	4
Age, y/sex	73/M	65/M	67/M	58/M
Occupation	Farmer	Retiree	Retiree	Retiree
Location (district) in Shanghai	Fengxian	Baoshan	Songjiang	Pudong
Disease history	Coronary heart disease; chronic hepatic schistosomiasis	Hypertension; articular gout; benign prostatic hyperplasia	None	Hypertension
History of poultry exposure	At home	At live poultry markets	At live poultry markets	At live poultry markets
Date of last visit to live poultry market	NA	2013 Mar 29	2013 Mar 28	2013 Mar 19
Date of symptom onset	2013 Mar 31	2013 Apr 1	2013 March 30	2013 Mar 20
Date of infection confirmation	2013 Apr 6	2013 Apr 6	2013 Apr 7	2013 Apr 7
Date admitted to SHPHCC	2013 Apr 6	2013 Apr 6	2013 Apr 7	2013 Apr 7
Clinical symptoms present when admitted SHPHCC	6 d of fever (maximum temperature 39.3°C) and shortness of breath	6 d of fever (maximum temperature 39.3°C), and 2 d of cough	8 d of fever (maximum temperature 39.7°C) and cough	18 d of cough, 10 d of fever (maximum temperature 39.7°C), and 5 d with shortness of breath
Chest radiograph or CT findings	Bilateral GGO	Bilateral GGO	GGO in left lingular lobe and left inferior lobe	Extensive infiltrates, with pleural effusion, in lung (bilateral)
Antiviral drug treatment	Oseltamivir (150 mg/bid) on days 7–12 of illness	Oseltamivir (75 mg/bid) on days 4–17 of illness	Oseltamivir (75 mg/bid) on days 6–21 of illness	Oseltamivir (75 mg/bid) on days 16–23 of illness; oseltamivir (150 mg/bid) on days 17–32 of illness
Antibacterial drug treatment	Moxifloxacin on days 7–12 of illness	Ceftriaxone on days 4–5 of illness; moxifloxacin on days 6–17 of illness	Azithromycin on days 5–9 of illness; cefaclor on days 1–5 of illness; moxifloxacin on days 14–21 of illness	Moxifloxacin on days 18–21 of illness; piperacillin and tazobactam on days 18–21 of illness; meropenem on days 21–34 of illness; linezolid on days 25–32 of illness
Glucocorticoid treatment	Methylprednisolone (40 mg/d) on days 7–12 of illness	No	Methylprednisolone (40 mg/d) on days 5–12 of illness	Methylprednisolone (40 mg/bid) on days 16–37 of illness
Immunoglobulin treatment	Yes, on days 7–12 of illness	Yes, on days 6–12 of illness	Yes, on days 5–8 of illness	Yes, on days 16–37 of illness
ECMO treatment	No	No	No	On day 25 of illness
Oxygen use	Noninvasive ventilation on days 6–12 of illness	Oxygen inhalation through nasal tube on days 4–17 of illness	Oxygen inhalation through nasal tube on days 7–20 of illness	Noninvasive ventilation on days 17–19 of illness
Endotracheal intubation and mechanical ventilation	Yes, on day 12 of illness	No	No	Yes, on days 19–32 of illness
Status as of 2013 Apr 21	Died on day 12 of illness	Recovered, discharged on day 18 after illness onset	Recovered, discharged on day 21 after illness onset	Condition worsened, receiving invasive breath machine and ECMO treatment

*NA, not applicable; SHPHCC, Shanghai Public Health Clinical Center; CT, computed tomography scan; GGO, ground-glass opacity; bid, 2 times a day; ECMO, extracorporeal membrane oxygenation.

Table 2. Laboratory findings at admission for 4 patients with early cases of influenza A(H7N9) virus infection, Shanghai, China

Laboratory variable	Case-patient no.				Reference value
	1	2	3	4	
Leukocyte count, $\times 10^9/L$	2.95	3.74	2.89	5.38	4.00–10.00
% Neutrophils	80.4	76.7	78.6	94.6	50.0%–70.0%
% Lymphocytes	13.5	18.2	15.4	2.4	20.0%–40.0%
Platelet count, $\times 10^9/L$	71	82	172	75	85–303
Aspartate aminotransferase, U/L	86	77	45	172	8–40
Lactate dehydrogenase, U/L	886	492	209	906	109–245
Creatine phosphokinase, U/L	170	1,854	170	772	38.00–174
Creatine kinase isoenzyme MB, U/L	18	31	7	22	0–24

Case-patient 3 arrived at SHPHCC with a nasal cannula inserted to maintain oxygen saturation at 95%. He had a history of hypertension and gout. He was treated with oseltamivir, antimicrobial drugs, and steroids to suppress lung inflammation. His condition improved substantially, and he was discharged 21 days after illness onset.

Case-patient 4 arrived at SHPHCC in critical condition: oxygen saturation was 88%, and he had shortness of breath (30–35 breaths/min). He was immediately given noninvasive mechanical ventilation. One day after admission, his condition deteriorated; multiple organ dysfunctions in lung and kidney developed. His condition continued to deteriorate despite active treatment with oseltamivir and antimicrobial drugs. Severe hypoxemia developed. Two days after admission, invasive mechanical ventila-

tion and then extracorporeal membrane oxygenation were implemented. The patient was still in critical condition on April 21, 2013.

Discussion

Clinical manifestations of disease in the 4 case-patients were consistent with those reported for other persons infected with influenza A(H7N9) virus (3). Case-patients 1 and 4 had a more severe disease course than case-patients 2 and 3. All patients sought medical care for unresolved fever, cough, expectoration of sputum, and shortness of breath. The severe cases progressed rapidly: body temperature was mostly sustained $\geq 39^\circ\text{C}$, and breathing was difficult and sometimes accompanied by hemoptysis. A rapid progression of acute respiratory distress syndrome

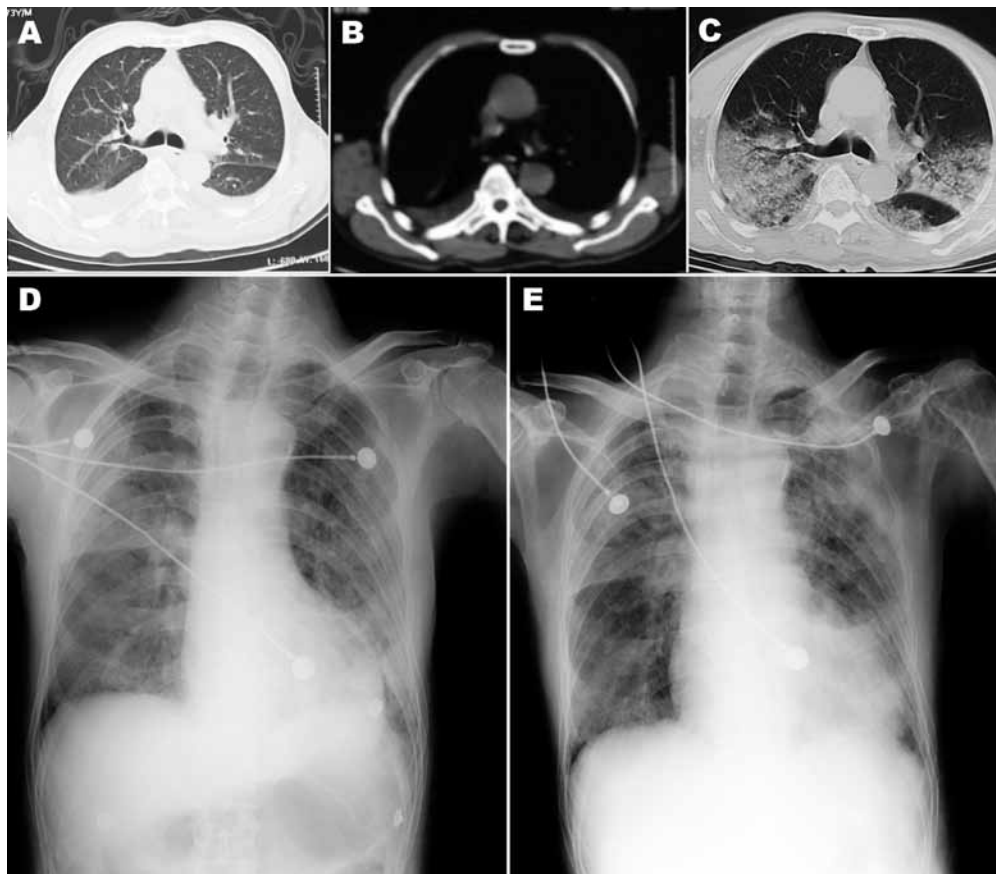


Figure 1. Chest computed tomography (CT) scan and radiograph images of patient (case-patient 1) in a study of 4 persons with early cases of influenza A(H7N9) virus infection, Shanghai, China. Images were taken 1, 5, 7, and 11 days after illness onset. A, B) CT scan images on day 1, showing bilateral pleural effusion but no obvious lesions. C) CT scan image on day 5, showing extensive ground-glass opacity and consolidation. D, E) x-ray images on days 7 and 11, respectively, showing reduced light transmittance on both sides of the lung.

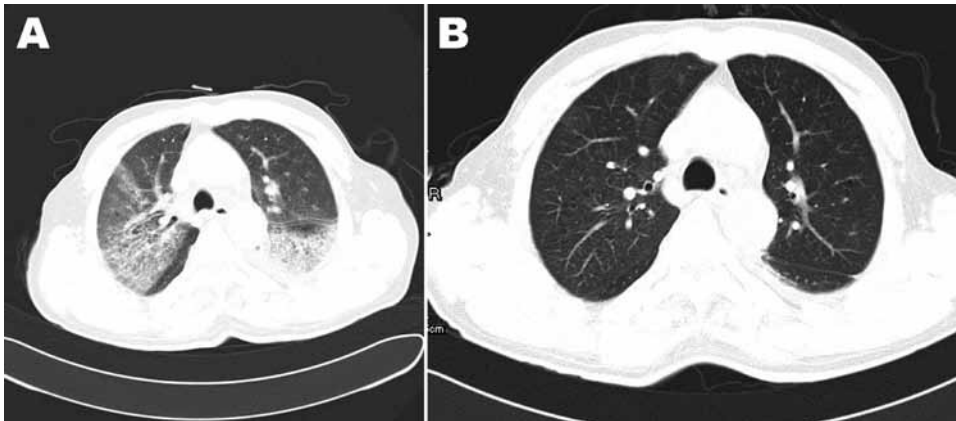


Figure 2. Chest computed tomography scan images of patient (case-patient 2) in a study of 4 persons with early cases of influenza A(H7N9) virus infection, Shanghai, China. A) Image taken 6 days after illness onset shows ground-glass opacity in the left lower and right upper lobes. B) Image taken 16 days after illness onset shows absorption of ground-glass opacity.

occurred in case-patients 1 and 4, along with mediastinal emphysema, shock, disturbed consciousness, and acute kidney injury. No close contacts of the 4 patients have had signs or symptoms of infection.

The currently available drug treatment for influenza A(H7N9) virus infection is neuraminidase inhibitors (e.g., oseltamivir). Their early use may be recommended (10) but is not always achieved. Case-patient 4 only began neuraminidase inhibitors 16 days after the onset of symptoms, by which time he was in a severe condition. Case-patient 1 was treated with oseltamivir 6 days after the onset of symptoms and, despite treatment, died 6 days after admission to SHPHCC. Earlier, higher doses combined with continuous treatment might improve patient outcomes (5). On the basis of clinical judgment, we now use 150 mg of oseltamivir twice daily for severe cases, monitoring for toxicity.

The benefits of oseltamivir treatment of influenza A(H7N9) virus infections are debatable; for example, case-patients 2 and 3 remained positive for the virus after 9–11 days of oseltamivir treatment (online Technical Appendix Table 1). Thus, it is essential to determine whether the virus has developed resistance to oseltamivir. Ineffectiveness of the oral oseltamivir formulations may also have contributed to treatment failure, especially for case-patients 1 and 4: the drug may not have been well absorbed, especially by patients in severe condition. If available in the future, systemic delivery of oseltamivir may be superior.

Of the 4 patients reported here, only case-patient 1 died shortly after admission to SHPHCC. He is also the only patient who had close contact with chickens. However, it is not clear that this contact contributed to the rapid progression of disease in case-patient 1, especially given the fact that case-patient 4, who is still in critical condition, also had rapid progression of disease. The other patients did not raise birds at home, but they visited live poultry markets.

Prompt and early communication of the clinical features of persons infected with avian influenza A(H7N9)

virus is crucial to the development of effective treatment strategies (6). Research to understand the transmission pattern and effective control of this virus is urgently needed (7–9).

Acknowledgment

We thank Thomas Marcinko for his invaluable help editing the manuscript.

This study was funded in part by the National Institute of Allergy and Infectious Diseases, National Institutes of Health, Department of Health and Human Services (contract no. HH-SN272200800014C).

Dr Lu is director of the Respiratory Department, SHPHCC, and is in charge of treatment and management of influenza A(H7N9) virus-infected patients. His primary interest is infectious diseases, especially tuberculosis in children.

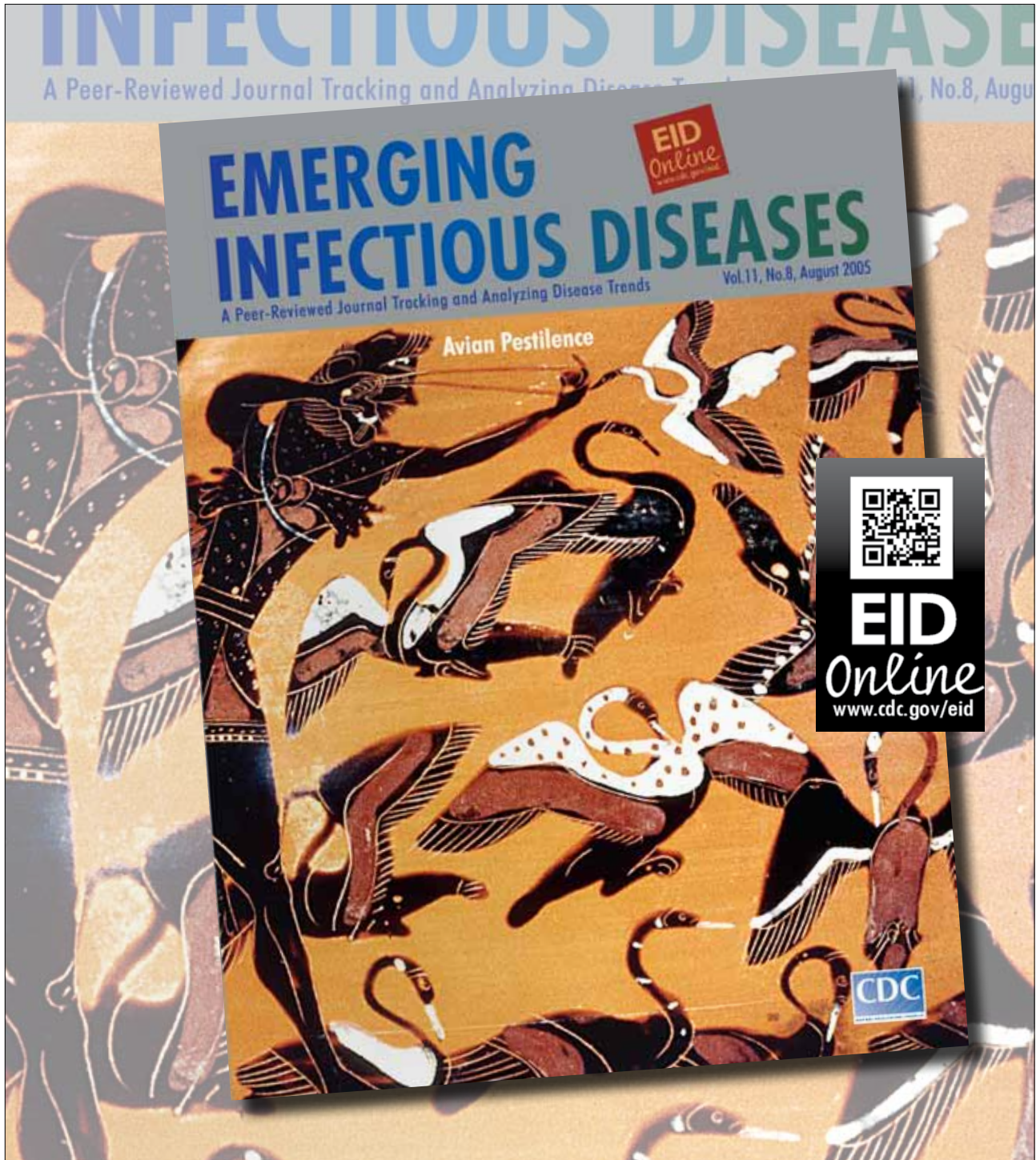
References

1. Parry J. H7N9 avian flu kills seven and infects 23 in China. *BMJ*. 2013;346:f2222. <http://dx.doi.org/10.1136/bmj.f2222>
2. Parry J. H7N9 avian flu infects humans for the first time. *BMJ*. 2013;346:f2151. <http://dx.doi.org/10.1136/bmj.f2151>
3. Gao R, Cao B, Hu Y, Feng Z, Wang D, Hu W, et al. Human infection with a novel avian-origin influenza A (H7N9) virus. *N Engl J Med*. 2013 [Epub ahead of print]. <http://dx.doi.org/10.1056/NEJMoa1304459>
4. Domínguez-Cherit G, Lapinsky SE, Macias AE, Pinto R, Espinosa-Perez L, de la Torre A, et al. Critically ill patients with 2009 influenza A(H1N1) in Mexico. *JAMA*. 2009;302:1880–7. <http://dx.doi.org/10.1001/jama.2009.1536>
5. White NJ, Webster RG, Govorkova EA, Uyeki TM. What is the optimal therapy for patients with H5N1 influenza? *PLoS Med*. 2009;6:e1000091. <http://dx.doi.org/10.1371/journal.pmed.1000091>
6. Uyeki TM, Cox NJ. Global concerns regarding novel influenza A (H7N9) virus infections. *N Engl J Med*. 2013 [Epub ahead of print]. <http://dx.doi.org/10.1056/NEJMp1304661>
7. Fauci AS, Collins FS. Benefits and risks of influenza research: lessons learned. *Science*. 2012;336:1522–3. <http://dx.doi.org/10.1126/science.1224305>

8. Patterson AP, Tabak LA, Fauci AS, Collins FS, Howard S. Research funding. A framework for decisions about research with HPAI H5N1 viruses. *Science*. 2013;339:1036–7. <http://dx.doi.org/10.1126/science.1236194>
9. Lurie N, Manolio T, Patterson AP, Collins F, Frieden T. Research as a part of public health emergency response. *N Engl J Med*. 2013;368:1251–5. <http://dx.doi.org/10.1056/NEJMs1209510>

Address for correspondence: Shuihua Lu, Shanghai Public Health Clinical Center, 2901 Caolong Rd, Jinshan, Shanghai 201508, Peoples' Republic of China; email: tubercle@shaphc.org

**Search past issues of EID
at wwwnc.cdc.gov/eid**



Clinical Findings for Early Human Cases of Influenza A(H7N9) Virus Infection, Shanghai, China

Technical Appendix

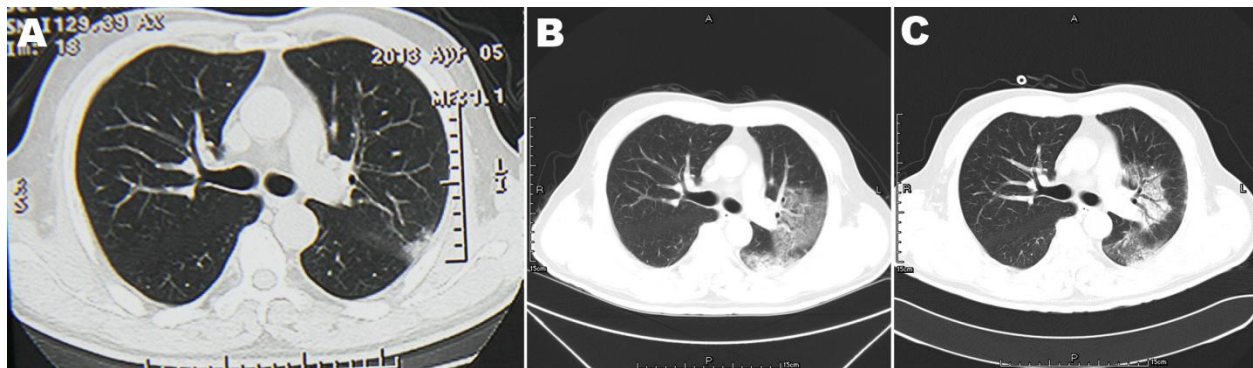
Technical Appendix Table 1. Virus detection in 4 patients with influenza A(H7N9) virus infection, Shanghai, China*

Case-patient	At admission			6–7 Days after admission		
	Day of illness	No. day(s) using oseltamivir	Virus detected	Day of illness	No. days using oseltamivir	Virus detected
1	6	1	Yes	12	7	Yes
2	5	2	Yes	12	9	No
3	8	4	Yes	15	11	No
4	18	2	Yes	25	9	Yes

*Patients were admitted to Shanghai Public Health Clinical Center for treatment after confirmation of infection.

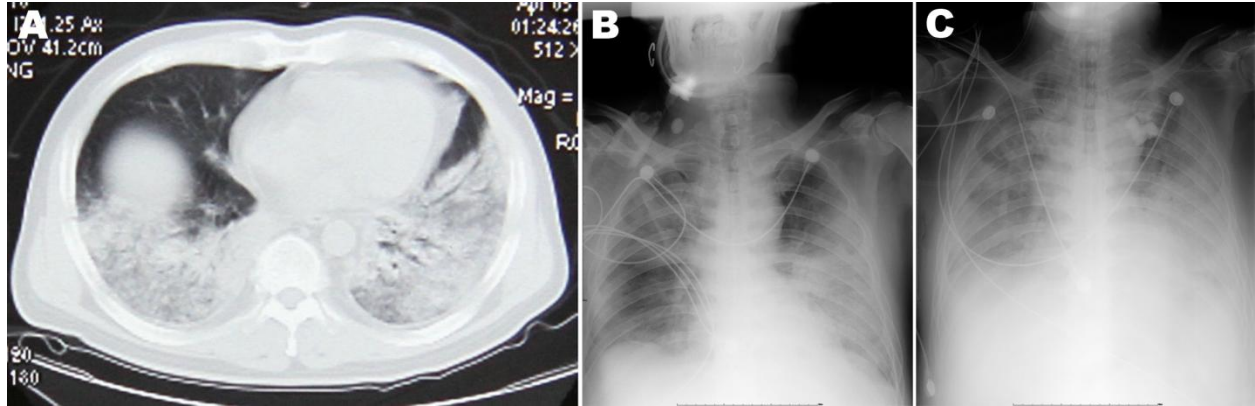
Technical Appendix Table 2. Comparison of H1N1, N5N1, and H7N9 in terms of epidemiology, symptoms, chest x-ray images, and disease prognosis

Variable	Influenza virus subtype		
	H1N1	H5N1	H7N9
Epidemiology	Patients as the main source of infection	History of environmental exposure to avian influenza	With or without history of environmental exposure to avian influenza
Symptoms	Cough, expectoration, polypnea, and poor appetite; main signs were moist rales and rough breathing sounds in lungs	Fever, the whole body muscle aches, fatigue, cough, purulent sputum, sometimes with blood or pus, chest pain, diarrhea	Fever, whole body muscle aches, fatigue, cough, purulent sputum, sometimes with blood or pus, chest pain, diarrhea
Chest x-ray images	Pneumonia, with or without pleural effusion	Pulmonary effusion, with or without pleural effusion	Pulmonary effusion, with or without pleural effusion
Disease prognosis	Generally good prognosis	Poor prognosis	Unknown



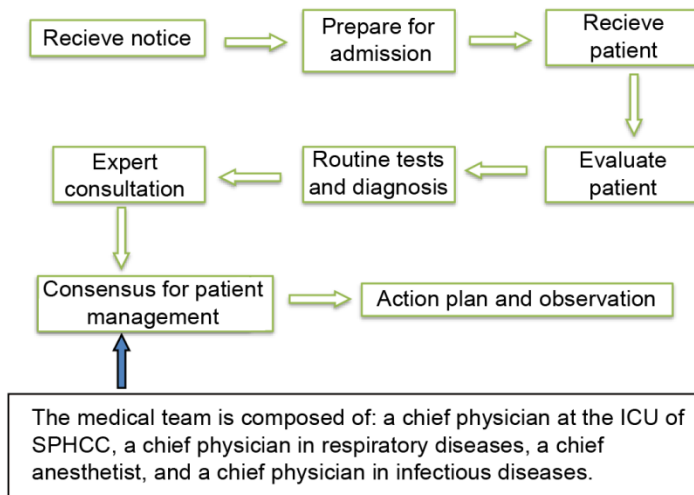
Technical Appendix Figure 1. Chest computed tomography scan images of patient 3, taken on days 6, 8, and 16 after the onset of illness. A) Only a little ground-glass opacity is present in the left upper lobe on

day 6. B) On day 8, the area of ground-glass opacity was enlarged, as seen in the left lingular and inferior lobes. C) Some absorption of the lesions was seen on day 16.



Technical Appendix Figure 2. Chest computed tomography scan and radiograph images of patient 4, taken on days 21, 24, and 28 after the onset of illness. A) The computed tomography scan image shows extensive bilateral lung infiltrates on day 21. B) The radiograph image shows areas of low light transmittance on both sides of the lung on day 24. C) The radiograph image shows larger areas of low light transmittance on day 28.

Procedures of HN7N9 patients admission, diagnosis, and treatment at the Shanghai Public Health Clinical Center (SPHCC)



Technical Appendix Figure 3. Procedures followed by an emergency team that was established at Shanghai Public Health Clinical Center (SHPHCC) for managing patients admitted for treatment of

confirmed influenza A (H7N9) virus infection, Shanghai, China. In brief, infection was confirmed and SHPHCC was notified before patients were transferred to the Center. Upon admission to SHPHCC, patients were evaluated thoroughly, and the disease condition was assessed. On the basis of the clinical diagnoses and results of routine laboratory tests, a consensus for managing, monitoring, and treating individual patients was established by a medical team composed of the chief physician in the SHPHCC intensive care unit, a chief physician in respiratory diseases, a chief anesthetist, and a chief physician in infectious diseases.